

Atrophic gastritis in a Shih-Tzu dog - case report

Gastrite atrófica em cão da raça Shih-Tzu - relato de caso

André Tobias Marques de Mattos^{1*}; Nilva Maria Freres Mascarenhas²;
Mariana Itimura Camargo de Mattos³; Carolina Grecco Grano Bordini³;
TaísaSchuartz Saragosa⁴

Abstract

We report the case of a female Shih-Tzu dog with chronic vomiting and hematemesis not responsive to symptomatic treatment. Due to the non-specific clinical signs, the patient underwent endoscopy and biopsy of the gastric mucosa. Histopathological analysis revealed atrophic gastritis, a disease rarely reported in dogs and characterized by the destruction of parietal cells of the mucosa and their replacement by fibrosis. This analysis allowed an adequate treatment based on the administration of corticosteroids by the anti-inflammatory effects and action in the regeneration of parietal cells, associated with a soft, hypoallergenic diet formulated with a low fat content, low digestible fibers, and high contents of complex carbohydrates, which resulted in the resolution of the clinical condition in a few weeks. In a second endoscopy, performed after eight months of treatment, the gastric mucosa presented a pink color, regardless of the degree of distension, no lesions or discontinuity points. Fragments were collected for histopathological analysis, which confirmed the recovery of gastric lesions and restoration of the macroscopically healthy mucosa. Most gastric diseases require histological analysis for a definitive diagnosis. In this context, endoscopy has brought unquestioned benefits to the patient since it allowed an accurate diagnosis with a quick and safe collection of gastric mucosa samples.

Key words: Biopsy. Gastritis. Gastroscopy.

Resumo

Relata-se o caso de uma cadela da raça Shih-Tzu com vômito crônico e hematêmese não responsivos ao tratamento sintomático. Devido aos sinais clínicos inespecíficos, a paciente foi submetida à endoscopia e biópsia da mucosa gástrica. A análise histopatológica revelou gastrite atrófica, doença raramente reportada em cães e caracterizada pela destruição das células parietais da mucosa e sua substituição por fibrose. Esta análise possibilitou o tratamento adequado, embasado na administração de corticosteróides, pelos efeitos antiinflamatórios e pela atuação na regeneração das células parietais, associada a uma dieta leve, hipoalergênica, formulada com baixos teores de gordura, pobre em fibras digeríveis e altos teores de carboidratos complexos, que resultou na resolução do quadro clínico em poucas semanas. Em uma segunda endoscopia, realizada após oito meses de tratamento, a mucosa gástrica se apresentava de coloração rósea, independentemente do grau de distensão, sem lesões ou pontos de descontinuidade. Foram colhidos fragmentos para análise histopatológica, que confirmou a recuperação das lesões

¹ Discente de Mestrado, Mestrado Profissional DCV/CCA, Universidade Estadual de Londrina, UEL, Londrina, PR, Brasil. E-mail: andretobiasmm@yahoo.com.br

² Profª Drª, Mestrado Profissional DCV/CCA, UEL, Londrina, PR, Brasil. E-mail: mascaren@uel.br

³ Médicas Veterinárias autônomas, Londrina, PR, Brasil. E-mail: mari.itimura@gmail.com; carol_grano@hotmail.com

⁴ Discente, Curso de Medicina Veterinária, Centro Universitário Filadélfia, UNIFIL, Londrina, PR, Brasil. E-mail: ts.saragosa@gmail.com

* Author for correspondence

gástricas e restabelecimento de mucosa macroscopicamente saudável. A maioria das doenças gástricas necessita de análise histológica para o diagnóstico definitivo. Neste contexto, a endoscopia trouxe benefícios incontestes à paciente, pois possibilitou o diagnóstico preciso com colheita de amostras de mucosa gástrica de forma rápida e segura.

Palavras-chave: Biópsia. Gastrite. Gastroscoopia.

Introduction

Atrophic gastritis is characterized by the destruction of parietal cells of the mucosa and its replacement by fibrosis (LECOINDRE; CHEVALLIER, 2000). This fact has been associated with loss of secretory gastric capacity resulting from an autoimmune process or chronic inflammatory gastropathy, eosinophilic, lymphocytic-plasmacytic or granulomatous gastritis (ROSSEAU, 2005). According to Willians (2000), the causes are unknown, reflecting chronic gastritis that may be associated with *Helicobacter* spp. The gastric carcinogenic process has been established in humans, which is a continuous process, evolving from non-atrophic to glandular atrophy, from metaplasia to dysplasia, and finally to adenocarcinoma, a process that occurs in decades and begins with bacterial infection by *Helicobacter* spp. (MELANIE; BRENNER, 2006). It is believed that Norwegian Lundehund dogs have a genetic predisposition of gastric carcinoma associated with atrophic gastritis (WILLIANS, 2000).

The most common clinical signs are vomiting, usually intermittent, anorexia, lethargy, and weight loss (WILLIANS, 2000). Rosseau (2005) reported as clinical signs anorexia and chronic vomiting lasting months, not responsive to symptomatic therapy. Basso et al. (2007) reported chronic sporadic vomiting every 15 or 20 days, observed since the five months of life in a dog.

As a means of diagnosing gastric diseases in dogs and cats, endoscopy is still a method not widespread in veterinary routine in Brazil. Considered as a safe, fast, and non-invasive technique, it assists in the diagnosis of gastrointestinal diseases, allowing the direct inspection of the mucosa and biopsies (SIMPSON, 1993). The examination has

been indicated for patients with nonspecific signs such as nausea, sialorrhea, vomiting, anorexia, hematemesis, and melena (TAM, 1999), suggestive signs of infiltrative, erosive or ulcerative gastropathy (FOSSUM, 2005). The histopathological analysis of the gastric mucosa is the definitive means of diagnosis, which can be obtained by endoscopy or partial gastrectomy by celiotomy or laparoscopy (ROSSEAU, 2005). In humans, the serum pepsinogen concentration (PG I and PG II) is also used as a diagnostic method and, in these cases, both PG I and the PG I/PG II ratio will be decreased in cases of chronic atrophic gastritis (MELANIE; BRENNER, 2006).

The treatment for atrophic gastritis is based on the use of corticosteroids, not only for its anti-inflammatory effects, but also for stimulating the regeneration of parietal cells (TWEDT; MAGNE, 1992), as well as the administration of a light, hypoallergenic diet with a formulation of low fat content, low digestible fibers, and high contents of complex carbohydrates (ROSSEAU, 2005). Because it is an underdiagnosed disease, the aim of this study was to report a case of atrophic gastritis in a Shih-Tzu dog breed, addressing the diagnosis obtained by endoscopic examination, treatment, and post-therapeutic follow-up of the patient.

Case Report

A 1-year-5-month-old female Shih-Tzu dog with a body mass of 4.8 kg was referred to an endoscopy service of a private clinic with a history of intermittent vomiting for 6 months, intensified in the last three weeks, starting with hematemesis. The patient has been treated for months with antacids (omeprazole), anti-emetics (ondansetron

and metoclopramide), and diets without improving the clinical condition. Screening exams, such as complete blood count, alanine aminotransferase (ALT), alkaline phosphatase (AP), urea, creatinine, and glucose, were initially performed with results within the reference values for the species. In addition, the patient was submitted to an abdominal ultrasonography, also without alterations. Due to the persistent clinical signs and the absence of alterations in complementary exams, the animal was then referred for an endoscopy.

For the examination, the patient underwent an eight-hour water fasting and twelve-hour food fasting. The anesthetic protocol started with intramuscular (IM) acepromazine (0.03mg kg^{-1}) and meperidine (3mg kg^{-1}) as a preanesthetic medication. After 20 minutes, the patient was induced with intravenous (IV) propofol at a dose of 5mg kg^{-1} , intubated, and maintained anesthetically under inhalation anesthesia with isoflurane. The device used was a Pentax video-endoscope model EPK 1000 and a Pentax gastroscope model EG-2970k. Exam images were obtained with an image capture software.

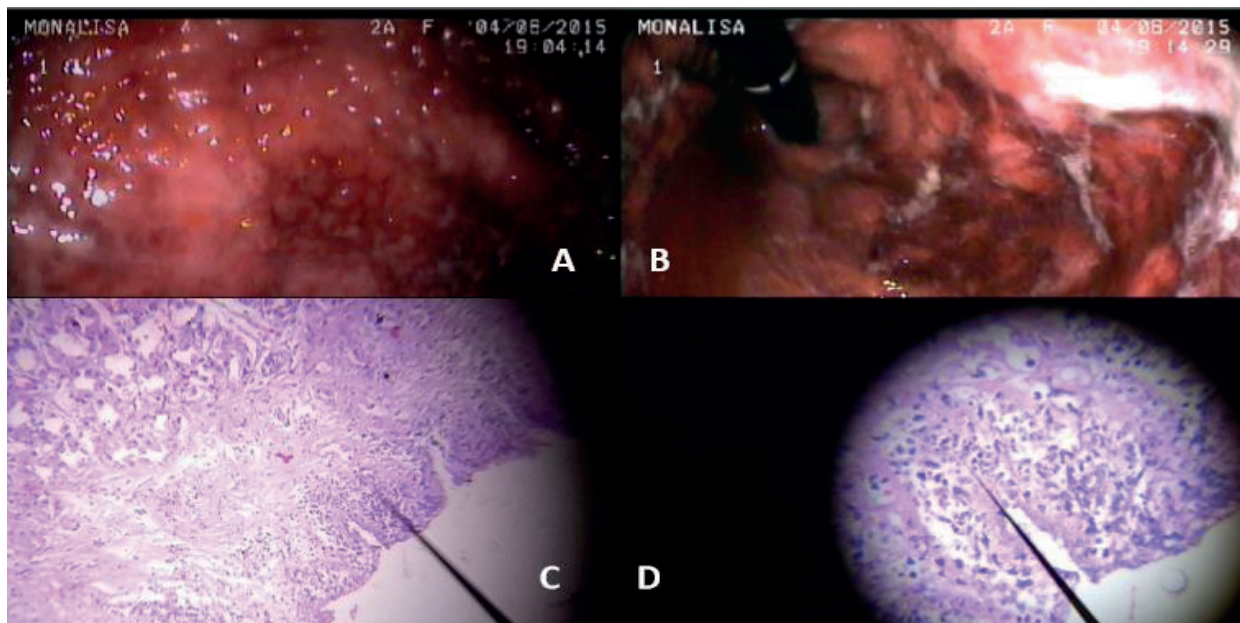
The fundus of the stomach presented accumulation of foamy saliva, as well as the region of the gastric body, in addition to a viscous and bloody fluid similar to that found in the esophagus. The stomach was washed by infusion and aspiration of water, being removed approximately 120 mL of the serosanguinolent fluid and salivary foam. During insufflation, we observed that the stomach did not distend adequately, especially in the region of the antrum canal. A part of the body of the stomach, examined with little distention by air, showed rugae with normal appearance, but with insufflation we detected a mucosa with edema, fibrin accumulation, and a marked, even hemorrhagic hyperemia. The affected area covered a large part

of the gastric body, extending to the fundus of the stomach and the entrance of the pylorus canal (Figure 1, A and B). Eight fragments of the stomach (fundus, body, and antrum canal) were collected at different points with lesions, from transitional areas and points with milder alterations. These samples were conditioned in Eppendorf tubes with 10% formaldehyde and subsequently processed and analyzed histopathologically in a specific laboratory.

The histopathological analysis revealed sequential cuts of the gastric mucosa, with some cuts partially presenting the muscular layer. We observed a mucosa with loss of villi associated with a significant erosion of their coating epithelium. At the site of epithelial denudation, a granulation layer with chronic inflammation (lymphocytic) and edema was noticed. Foci of ulceration were also observed, with thinning of the glandular layer, as well as a glandular epithelium presenting a high degree of degeneration and partial glandular atrophy with local fibrosis. In other parts, there was still a presence of villus fusion. These characteristics are suggestive of chronic atrophic ulcerative gastritis (Figure 1, C and D).

After exam results, a treatment was started with omeprazole (1 mg kg^{-1} SID) via oral (VO) for 30 days, sulfamethoxazole (20mg kg^{-1} VO BID) for 7 days, sucralfate (25mg kg^{-1} VO TID) for 20 days, ondansetron (0.2mg kg^{-1} VO TID) for 5 days, prednisone (1mg kg^{-1} VO BID), and a soft diet (cooked shredded chicken breast, rice, potatoes, and carrots). At the subsequent return, 15 days after starting treatment, the owner reported an 80% improvement in the clinical condition. The patient had no more vomiting, was alert, willing, being also reported normophagia and normal defecation. The gradual reduction of corticosteroid therapy was started in the following months until the dose of 0.2 mg kg^{-1} VO SID.

Figure 1. Atrophic gastritis in a dog. A) Edema, hyperemia, and hemorrhagic lesions in a gastric mucosa, a region of the gastric body. B) Hyperemia and hemorrhagic lesions in a gastric mucosa, pyloric region. C and D) Glandular epithelium of the gastric mucosa presenting a high degree of degeneration, glandular atrophy, fibrosis, and fusion of villi.



Eight months after starting the treatment, the animal was submitted to a new endoscopy for gastric surface reassessment and biopsy for histopathological examination. The anesthetic protocol, endoscopy device used, and the team of veterinarians (anesthesiologist, endoscopist, and auxiliary) were the same as those of the previous maneuver. During the macroscopic assessment of the gastric mucosa, unlike the first assessment, there were no contents in the stomach, such as saliva, blood or food residues. In this second examination, the insufflation difficulty was also observed, but to a lesser degree, the gastric mucosa presented a pinkish color, irrespective of the degree of distension, and no lesions were noticed at any point, in either the fundus, body, or antrum canal. Discontinuity in the mucosa was no longer observed. Biopsy material was collected from the same regions of the previous examination and conditioned in the same way, followed by analysis by the same veterinarian pathologist. We observed recovery of gastric lesions

and restoration of macroscopically healthy mucosa (Figure 2A and B).

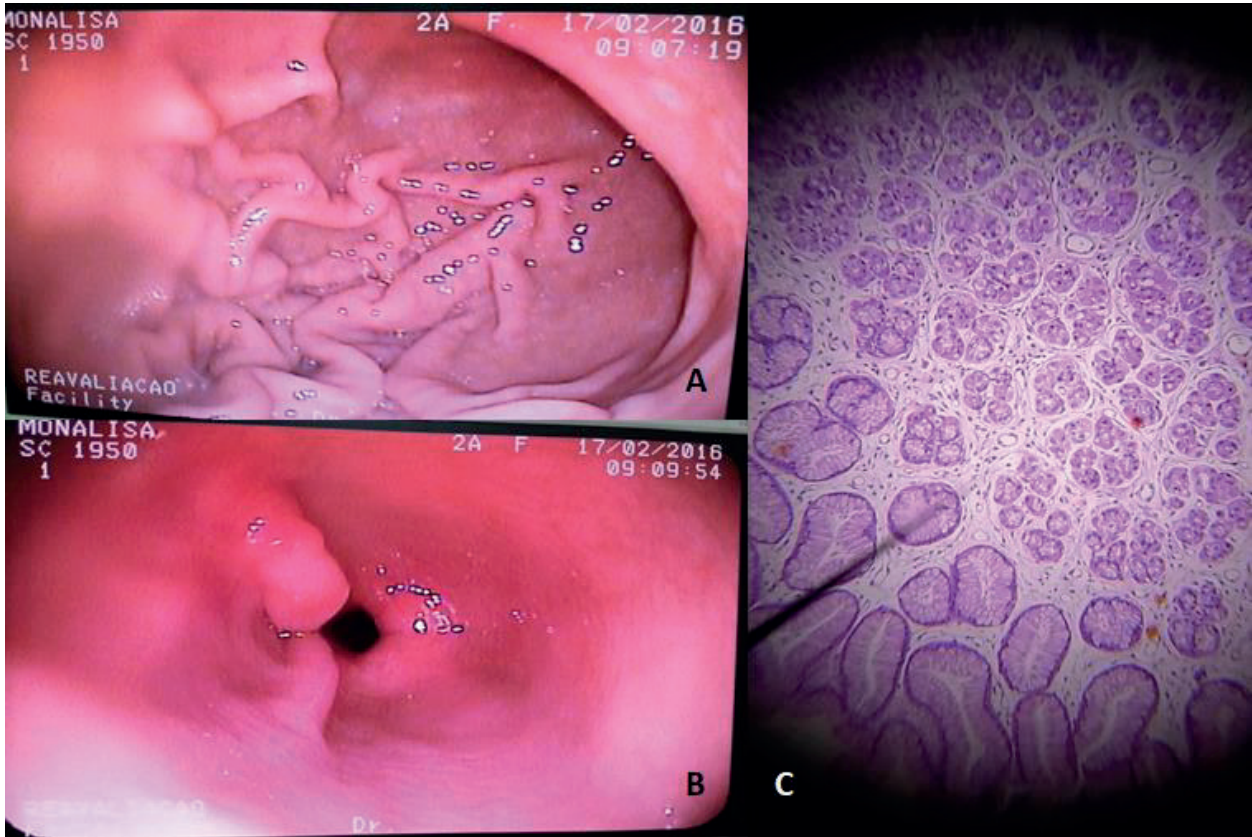
The histopathological analysis of samples revealed histological characteristics compatible with gastric mucosa, some discretely distorted gastric glands, and discrete lymphoplasmacytic infiltrate. In some cuts, there was a discreet congestion of superficial vessels, discrete edema in the lamina propria. The epithelium was preserved. No structures suggestive of helicobacteria were observed. These characteristics are compatible with discrete chronic lymphoplasmacytic gastritis. In comparison to the previous examination, no ulcerative lesions were observed. Glandular distortion may be associated with their regeneration (Figure 2C).

Nine months after starting the treatment, cyclosporine was introduced as an attempt to reduce the corticosteroid dose, but the animal presented worsening of the clinical condition, with vomiting and diarrhea even before the corticoid

dose reduction. Therefore, cyclosporine was discontinued and the corticosteroid was maintained at a dose of 0.2 mg kg⁻¹ VO on alternate days until

the present day, totaling a period of 1 year and 8 months of follow-up.

Figure 2. Atrophic gastritis in a dog after treatment. A and B) Gastric mucosa recovered from lesions and macroscopically healthy. C) Glandular regeneration of the gastric mucosa.



Discussion

Atrophic gastritis is an underdiagnosed disease in animals, with little reports (SHAW; IHLEN, 1999). Its etiology is unknown, but it is known that prolonged use of gastric acid secretion inhibitors, such as omeprazole, may result in gastric gland atrophy (STURGESS, 2001). In the case reported in this study, the patient started with episodes of sporadic vomiting at 11 months of age, which intensified in the following six months, and no previous medication was reported by the owners before the beginning of clinical signs, such as gastric

protectors. In this case, identifying the etiology was not possible, but the influence of gastric protectors as a causative agent is ruled out.

The most common clinical signs are vomiting, which may be continuous or intermittent, but rarely hematemesis is observed (STURGESS, 2001; BASSO et al., 2007). These studies differ from our report, in which vomiting was observed for six months, sporadic, evolving to severe hematemesis in the last weeks, which is probably due to the associated inflammatory gastritis observed in the histopathological analysis.

The definitive diagnosis of atrophic gastritis is only possible through the histopathological analysis of the gastric mucosa. This is probably the reason for being rarely reported (ROSSEAU, 2005). Endoscopy allows direct visualization and sampling of the gastric mucosa for cytological and histopathological analysis and has proven to be an accurate method for the diagnosis of gastrointestinal diseases (JERGENS et al., 1998). In this patient, for whom conventional exams and empirical treatments were ineffective, the use of endoscopy for direct assessment and collection of material for histopathological assessment was essential for the definitive diagnosis of atrophic gastritis.

Sturgess (2001) describes the histopathological alterations found in atrophic gastritis as diffuse lesions with thinning of the mucosa and decrease in size and depth of the gastric glands, resulting in a flat mucosal epithelium and smaller and deformed rugae, in addition to an inflammatory infiltrate. In our report, we observed a gastric mucosa with granulation and lymphocytic infiltrate, a characteristic of chronic inflammation, edema, foci of ulceration, and glandular atrophy presenting a high degree of glandular degeneration with local fibrosis, which is in agreement with those observed in the literature.

Immunosuppressive therapy is indicated when tissue samples demonstrate a predominance of lymphocytes and plasmocytes, suggesting an immune-mediated process (TWEDT; MAGNE, 1992). Basso et al (2007) reported the use of methylprednisolone sodium succinate at doses of 2 mg kg⁻¹ IV BID for seven consecutive days, followed by a reduction to 1 mg kg⁻¹ IV BID for more seven days. The gradual reduction continued until the dose of 0.25 mg kg⁻¹ VO SID for undetermined time. This patient presented the resolution of the clinical condition for a period of 18 months. Rosseau (2005) reported the treatment in a Labrador Retriever using prednisone 1mg kg⁻¹ VO BID for seven days, with a dose reduction to 0.75mg kg⁻¹ VO BID for more three weeks associated with a hypoallergenic diet.

After the eighth week of treatment, the owner stopped the treatment and the animal showed no clinical signs for a period of eight months. For the patient reported in our study, treatment started with omeprazole (1mg kg⁻¹ VO SID) for 30 days, sulfamethoxazole (20mg kg⁻¹ VO BID) for 7 days, sucralfate (25mg kg⁻¹ VO TID) for 20 days, ondansetron (0.2mg kg⁻¹ VO TID) for 5 days, prednisone (1mg kg⁻¹ VO BID), and a soft diet (cooked shredded chicken breast, rice, potatoes, and carrots). Fifteen days after starting the treatment, corticoid dose was gradually reduced to 0.2mg kg⁻¹ VO on alternate days, being this dose established for this patient. This case confirms and supports the reports observed in the literature regarding the treatment, in which corticotherapy is necessary for patients with atrophic gastritis. Still, according to Rosseau (2005), the treatment for atrophic gastritis is not defined, but a diet with high contents of complex carbohydrates, low-fat contents, and poor in non-digestible fibers is important. Basso et al. (2007) point out that continued use of corticosteroids, even at low doses, may result in side effects, but the benefits justified the use, overcoming the harms.

After eight months of treatment, with a resolution of clinical signs, the patient underwent a new endoscopy for control and reassessment of the gastric mucosa. In this examination, stomach distension was more efficient when compared to the first examination, but it still did not reflect an expected distension capacity of a normal stomach for the species. The coloration of the mucosa of the body, fundus, and pyloric antrum was pink, without lesions/ulcers/erosions or mucosal defects. These are images very different from those observed in the first examination, where the mucosa was hemorrhagic, edematous, and with discontinuity areas. This macroscopic assessment post-treatment revealed a gastric mucosa apparently healthy, but with loss of its distension capacity. Lecoinde and Chevallier (2000) suggest that the replacement of parietal cells of the gastric mucosa by fibrosis is due to the resolution of the inflammation of these cells.

Despite a subjective and non-measurable assessment of gastric distension capacity, a correlation may be established between this decrease in distension and the fibrosis reported by Lecoinde and Chevallier (2000). No data were found in the literature to prove this theory.

Post-treatment histopathological analysis revealed some discretely distorted gastric glands with discrete lymphoplasmacytic infiltrate with congestion of superficial vessels in some cuts, in addition to edema in the lamina propria. The epithelium was preserved. No structures suggestive of helicobacteria were observed. In comparison to the pre-treatment examination, where epithelial erosion and especially ulceration foci were observed, the gastric mucosa was recovered substantially, which corroborates the macroscopic assessment of the mucosa performed by endoscopy and resolution of the clinical condition. Despite these positive results, the presence of discrete chronic lymphoplasmacytic gastritis was still concluded, which justifies the maintenance of the corticosteroid therapy, a drug that the animal makes continuous and uninterrupted use since diagnosis. The glandular distortion observed in the histopathology may be associated with the regeneration of the glands, which, according to Twedt and Magne (1992), may have been stimulated by the use of corticosteroids, which besides its anti-inflammatory benefits may benefit the regeneration of parietal cells. Rosseau (2005) states that after removing the causative agent, clinical signs and histological alterations are reversible. In this reported case, etiology was not identified, as in the report of Basso et al. (2007), which also according to Rosseau (2005) is a good prognosis for disease control, but unsatisfactory for its cure.

Conclusion

Endoscopy was effective for a definitive diagnosis of atrophic gastritis in this case report and it is indicated for all patients presenting chronic vomiting not responsive to symptomatic treatment.

References

- BASSO, P. C.; BRUN, M. V.; SCHMIDT, C.; BARCELLOS, D. L.; GRAÇA, D. L. Cirurgia laparoscópica no diagnóstico de gastrite crônica atrófica seguida de tratamento clínico em cadela: relato de caso. *Arquivo Brasileiro de Medicina Veterinária e Zootecnia*, Belo Horizonte, v. 59, n. 5, p. 1205-1210, 2007.
- FOSSUM, T. W. *Cirurgia de pequenos animais*. 2. ed. São Paulo: Rocca, 2005. 1408 p.
- JERGENS, A. E.; ANDREASEN, C. B.; HAGEMOSER, W. A. Cytologic examination of exfoliative specimens obtained during endoscopy for diagnosis of gastrointestinal tract disease in dog and cats. *Journal of the American Veterinary Medical Association*, Schaumburg-IL, v. 213, n. 12, p. 1755-1759, 1998.
- LECOINDRE, P.; CHEVALLIER, M. Gastrites chroniques. In: LAFORGE, H.; GROULADE, P. *Encyclopédie vétérinaire*. Paris: Encyclopédie Médico Chirurgicale, 2000. v. 3, p. 1-6.
- MELANIE, N. W.; BRENNER, H. Prevalence of chronic atrophic gastritis in different parts of the world. *Cancer Epidemiology, Biomarkers & Prevention*, Philadelphia, v. 15, n. 6, p. 1083-1094, 2006.
- ROSSEAU, M. Severe lymphocytic-plasmacytic and atrophic gastritis, as well as, predominantly eosinophilic, severe enteritis, in a 19-month-old Labrador retriever. *Canadian Veterinary Journal*, Guelph, v. 46, n. 3, p. 264-267, 2005.
- SHAW, D.; IHLE, S. Doenças gastrointestinais. In: _____. *Medicina interna de pequenos animais*. Porto Alegre: Artmed, 1999. cap. 41, p. 287-289.
- SIMPSON, K. W. Gastrointestinal endoscopy in dog. *Journal of Small Animal Practice*, Oxford, v. 34, n. 4, p. 180-188, 1993.
- STURGESS, C. P. Doenças do trato alimentar. In: DUNN, J. K. *Tratado de medicina Interna de pequenos animais*. São Paulo: Roca, 2001. cap. 36, p. 367-443.
- TAM, T. R. *Small animal endoscopy*. 2th ed. Missouri: Mosby, 1999. 497 p.
- TWEDT, D. C.; MAGNE, M. L. Moléstias do estômago. In: ETTINGER, S. J. *Tratado de medicina interna veterinária: moléstias do cão e gato*. 3. ed. São Paulo: Manole, 1992. v. 3, cap. 85, p. 1367-1369.
- WILLIAMS, D. A. Gastritis atrophic. In: TILLEY, L. P.; SMITH, F. W. K. *The 5-minute veterinary consult canine and feline*. Baltimore: Lippincott Williams & Wilkins, 2000. CD-ROM.

