

Functional neurologic recovery in two dogs diagnosed with severe luxation of the vertebral column

Recuperação da função neurológica em dois cães com deslocamento grave da coluna vertebral

Mônica Vicky Bahr Arias^{1*}; Daniela Scapini Mendes²; Nazilton de Paula Reis Filho³

Abstract

Traumatic injuries to the vertebral column, spinal cord, and cauda equina nerve roots occur frequently in human and veterinary medicine and lead to devastating consequences. Complications include partial or complete loss of motor, sensory, and visceral functions, which are among the main causes of euthanasia in dogs. The present case report describes neurological functional recovery in two dogs that were treated surgically for severe spinal fracture and vertebral luxation. In the first case, a stray, mixed breed puppy was diagnosed with thoracolumbar syndrome and Schiff-Scherrington posture, as well as a T13 caudal epiphyseal fracture with 100% luxation between vertebrae T13 and L1; despite these injuries, the animal did show deep pain sensation in the pelvic limbs. Decompression through hemilaminectomy and spinal stabilization with vertebral body pins and bone cement were performed, and the treatment was supplemented with physiotherapy and acupuncture. In the second case, a mixed breed dog was diagnosed with a vertebral fracture and severe luxation between L6 and L7 after a vehicular trauma, but maintained nociception and perineal reflex. Surgical stabilization of the spine was performed using a modified dorsal segmental fixation technique. Both patients showed significant recovery of neurological function. Complete luxation of the spinal canal observed radiographically does not mean a poor prognosis, and in some cases, motor, sensory, and visceral functions all have the potential for recovery. In the first case the determining factor for good prognosis was the presence of deep pain perception, and in the second case the prognosis was determined by the presence of sensitivity and anal sphincter tone during the initial neurological examination.

Key words: Nervous system, spinal cord, dogs

Resumo

Lesões traumáticas à coluna vertebral, medula espinhal e raízes nervosas da cauda equina ocorrem frequentemente na medicina veterinária e humana, levando a sequelas devastadoras, como perda parcial ou completa das funções motoras, sensoriais e viscerais, sendo a ocorrência destas sequelas uma das principais causas de eutanásia em cães. O objetivo do presente trabalho é relatar a recuperação da função neurológica em dois cães com fratura vertebral e deslocamento do canal medular de mais de 100% tratados cirurgicamente. O primeiro caso ocorreu em um filhote de cão sem raça definida (SRD) encontrado na rua com síndrome toracolombar e presença de postura de Schiff-Scherrington, constatando-se fratura em epífise caudal do corpo vertebral de T13 com luxação grave entre as vértebras

¹ Prof^o Dr^a, Dept^o de Clínicas Veterinárias, Universidade Estadual de Londrina, UEL, Londrina, PR, Brasil. E-mail: vicky@uel.br

² Médica Veterinária, Hospital Veterinário, Centro Universitário Filadélfia, UNIFIL, Londrina, PR, Brasil. E-mail: dani_scapini@hotmail.com

³ Pós Graduando, Faculdade de Ciências Agrárias e Veterinárias, Universidade Estadual Paulista, UNESP, Jaboticabal, SP, Brasil. E-mail: nazilton@hotmail.com

* Author for correspondence

T13 e L1, porém o animal apresentava sensibilidade dolorosa profunda em membros pélvicos. O tratamento utilizado neste caso foi descompressão através de hemilaminectomia e estabilização da coluna com pinos nos corpos vertebrais e cimento ósseo, além de fisioterapia e acupuntura. O segundo caso ocorreu em cão SRD atropelado, que apresentou fratura e luxação entre L6, L7 e grande desvio entre os fragmentos, que porém apresentava nocicepção e reflexo perineal preservado. O tratamento realizado foi a estabilização da coluna através da técnica de fixação segmentar dorsal modificada. Ambos os pacientes apresentaram recuperação significativa da função neurológica, permanecendo com discreta paresia de membros posteriores. O deslocamento de 100% do canal vertebral à avaliação radiográfica não significa prognóstico ruim, havendo em alguns casos chance de recuperação das funções motoras, sensoriais e viscerais. No primeiro caso o fator determinante para o bom prognóstico foi a presença de percepção da dor profunda, e no segundo caso, o prognóstico foi determinado pela presença de sensibilidade e tônus no esfíncter anal durante o exame neurológico inicial.

Palavras-chave: Sistema nervoso, medula espinhal, cães

Introduction

Spinal trauma occurs frequently in canine and feline clinical practice and causes various neurological changes, life-threatening injuries (BRAUND, 2003), and long term complications resulting in euthanasia (MENDES; ARIAS, 2012). Diagnosis is based on medical history, clinical and neurological examination, and imaging (SHARP; WHELEER, 2005; KINNS et al., 2006). Once the patient is stabilized and the neurologic injury localized, radiographs of the vertebral column must be performed to assess the fracture and its stability (SHARP; WHELEER, 2005; KINNS et al., 2006). The radiographic findings may be normal (KINNS et al., 2006) or may reveal vertebral fractures, luxation, or s luxation, which may or may not cause spinal cord injuries (SHARP; WHELEER, 2005; KINNS et al., 2006). Computed tomography (CT) and mainly magnetic resonance imaging (MRI) can assess the spinal cord parenchyma and spinal nerve roots status (SHARP; WHELEER, 2005), but this technology is still unavailable in most parts of our country.

Radiography does not replace neurological examination in patient assessment. Many authors agree that it is not possible to estimate the severity of neurologic dysfunction simply by radiographic examination, unless there is complete vertebral luxation (SHARP; WHELEER, 2005; WEH;

KRAUS, 2013). Therefore, the main prognostic factor in characterizing the severity of the spinal injury is deep pain perception (SHARP; WHELEER, 2005; ARAÚJO et al., 2012; WEH; KRAUS, 2013). Non-myelinated fibers, particularly in the propriospinal and spinoreticular tracts in the spinal cord, localized close to the junction of gray and white matter are responsible for transmitting the sensation of pain, and only a serious spinal cord injury is capable of destroying these fibers (SHARP; WHELEER, 2005), hence, animals that lose deep pain perception have a poor prognosis (KUBE; OLBY, 2008; WEH; KRAUS, 2013). For fractures located at the final section of the vertebral column, which compromise the cauda equina, the consequences of spinal injury are usually tail paralysis, urinary incontinence, and sensory alterations in the perineum (SHARP; WHELEER, 2005). There is only one report of functional recovery in two dogs with 100% vertebral displacement of vertebrae on radiographs after experiencing trauma (ARAÚJO et al., 2012).

A three-compartment model, initially used in human medicine and adapted to veterinary medicine, was used to classify the spinal column stability following trauma. Briefly, the spine is divided into dorsal, middle, and ventral sections; if more than one compartment is compromised, the fracture is considered unstable, and surgical stabilization is required (SHARP; WHELEER, 2005; KINNS et al., 2006). Most animals experiencing severe spinal

luxation and instability have a high risk of spinal cord transection or cauda equina lesion. Therefore, the present case study describes two cases of 100% spinal luxation in dogs, which were surgically treated with good results.

Case report

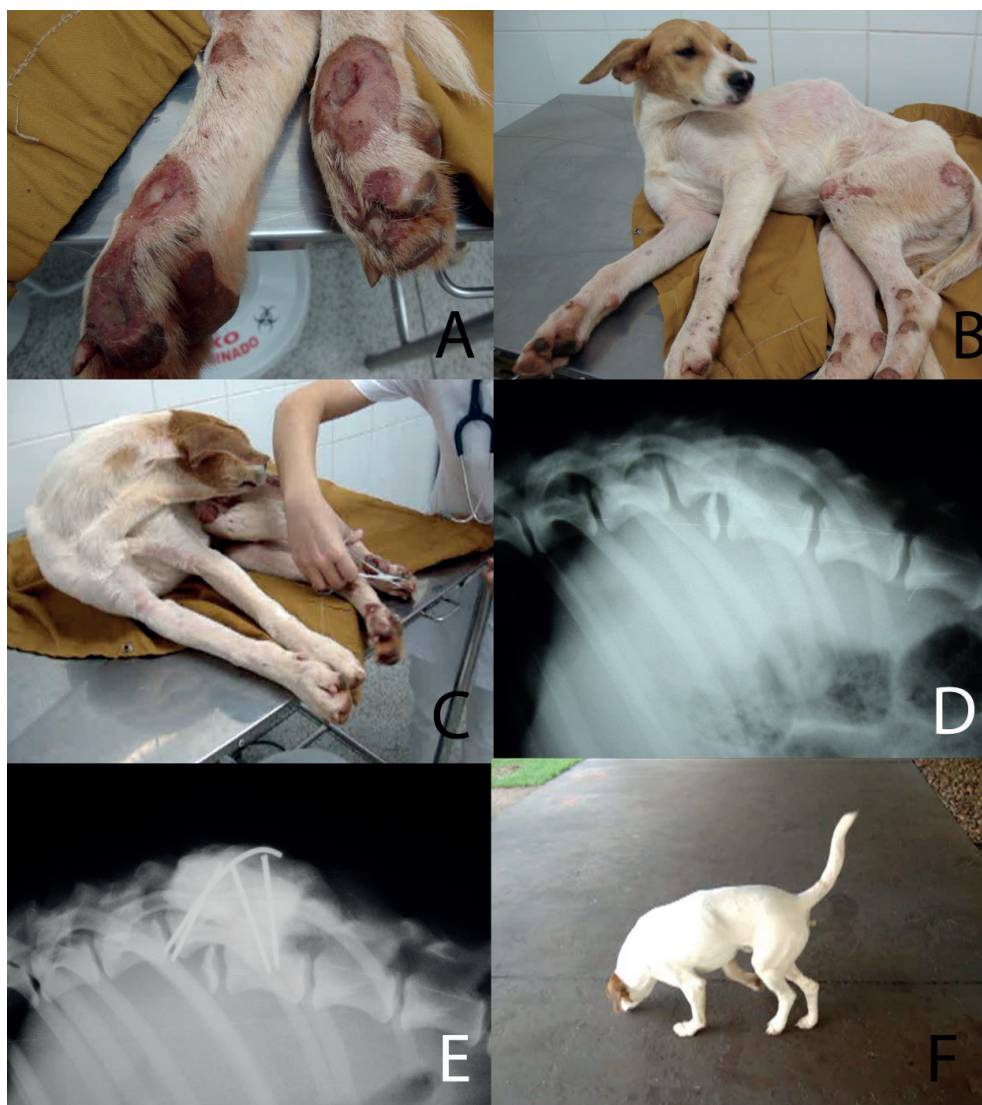Case 1

An approximately 10-month-old, intact male, mixed-breed dog weighing 13 kg was found on the streets with no previous medical history. Physical examination revealed circular infected wounds on the ischial tuberosity, distal third of the left and right femur extending into the tibiotarsal joints, with exposed bone at the digits (Figure 1a). The distal femur was displaced, and we observed soft tissue swelling in the distal third of the right femur, bilateral hind limb muscle atrophy, and dorsal thoracolumbar displacement. Neurological examination revealed paraplegia and a Schiff-Scherrington posture (Figure 1b), urinary retention, lack of sensitivity to superficial pain, and presence of deep pain perception (Figure 1c); the cutaneous trunci reflex was decreased up to the first lumbar vertebra. Collectively, these clinical signs indicated fourth-degree thoracolumbar syndrome. Thoracolumbar spinal radiographs showed an epiphyseal fracture of the T13 vertebral body, with a 100% luxation between vertebrae T13 and L1 (Figure 1d). A radiograph of the right posterior limb revealed a complete diaphyseal fracture in the distal third of the femur. We concluded that the animal had suffered trauma that caused the spinal and right femur fractures several days earlier, and that the

decreased nociception caused it to injure its limbs, thereby leading to infected wounds.

The wounds were cleaned with saline solution and covered with a bandage, and the animal received antibiotics (30 mg/kg cephalexin, every 8 h) and analgesics (3 mg/kg tramadol, every 8 h). After 4 days of medical management, spinal decompression surgery was performed to reduce the fracture and luxation and stabilize the thoracolumbar spine. Intense fibrosis post-injury made it impossible to reduce the thoracolumbar luxation; therefore, a hemilaminectomy was performed between T13 and L1, and bone fragments were removed from within the spinal canal, at which time the spinal cord was confirmed intact. Despite the fibrosis, 2 Schanz pins (2 mm) were inserted into the T13 vertebral body and 2 pins into the L1 vertebral body, and fixed with bone cement (Figure 1e). Due to the chronicity of femur fracture and presence of an infected wound over the limb, it was not surgically repaired. Postoperatively, cephalexin and tramadol were continued at the previously prescribed dosages. Twenty days postoperatively, the patient regained continence and superficial sensitivity, but continued to show severe paraparesis. Physiotherapy and acupuncture were performed, and 4 months after surgery, the patient was ambulatory with a slight proprioceptive ataxia and remained continent (Figure 1f). The patient was then monitored for 180 days and showed a significant improvement both clinically and neurologically. Superficial sensitivity remained intact; the animal wagged its tail voluntarily and showed normal locomotion and controlled urination and defecation.

Figure 1. Photographs of a mixed breed dog, approximately 10 months old, weighing 13 kg, diagnosed with a fractured T13 vertebral body and luxation between vertebrae T13 and L1. 1a. infected wounds on digits of the posterior limbs with bone exposed; 1b. Schiff-Scherrington posture and wounded bony protuberances of the ischial tuberosity, stifle, and tibiotarsal joints; 1c. A conscious response of the patient is observed when testing deep nociception; 1d. Pre-operative radiography of the thoracolumbar spine, revealing a fractured caudal epiphysis of the T13 vertebral body with luxation between vertebrae T13 and L1, and complete vertebral canal luxation; 1e. Postoperative radiography of the thoracolumbar spine. 1f. The patient walking, with an erect tail, and without wounds 110 days after surgery.



Case 2

We evaluated an adult male mixed breed dog weighting 5 kg, with a history of pelvic limb gait abnormalities following vehicular trauma. Physical examination of the animal revealed perineal hematomas, crepitation in the pelvis, and lumbar pain. Neurological examination showed pelvic limb paresis, a normal patellar reflex, withdrawal reflex

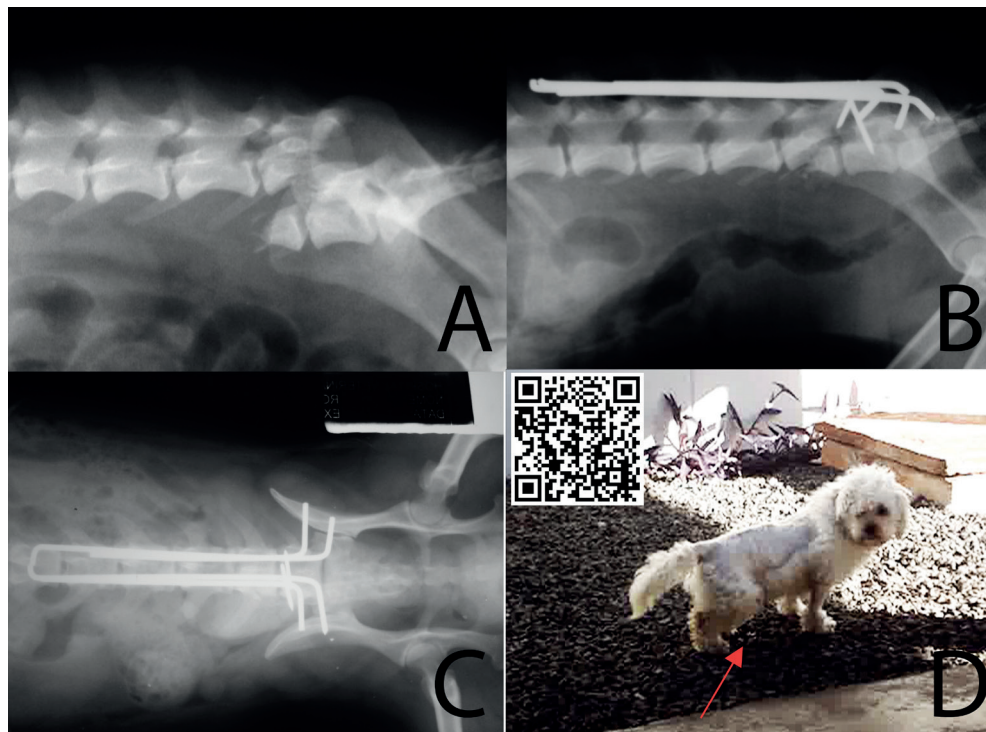
decreased, normal sensitivity to superficial pain in the hindlimbs and a normal cutaneous trunci reflex. There was a flaccid tail and urinary incontinence; however perineal reflex and perineal skin sensitivity were normal. Based on neurological examination, the canine was diagnosed with a lumbosacral syndrome. Pelvic radiography revealed a fractured right ischium and radiographs of the lumbosacral

spine revealed an oblique fracture of the L6 vertebral body with a large displacement between L6 and L7 (Figure 2a).

The dog received analgesics (0.2 mg/kg morphine, every 8 h), and after 2 days of medical management and cage rest, surgical stabilization of the lumbosacral column was performed using the modified dorsal segmental fixation technique (Figures 2b and 2c), and Steinmann pins (1 mm) were used to reduce the fracture. The pins were inserted into the L6-L7 articular processes, followed by the fixation of 4 Steinmann pins (1.5 mm) to the base of dorsal spinous processes and articular facets, with

number 2 nylon suture, as described by Pedro Neto et al. (2002). Postoperatively, enrofloxacin (5 mg/kg, every 12 h), carprofen (2.2 mg/kg, every 12 h), dipyrone (25 mg/kg, every 8 h), and morphine (0.1 mg/kg, every 4 h) were administered, and bladder massage was performed every 6 h. Six days after surgery, the patient recovered urinary continence, including being able to squat during urination (Figure 2d), and after 30 days, showed only slight paraparesis. The dog did not receive physiotherapy. The patient was monitored for 154 days after treatment and showed full recovery of locomotion and urinary continence, mild tail paresis was the only lasting effect.

Figure 2. Photographs of an adult mixed breed dog, weighing 5 kg, diagnosed with a lumbosacral lesion. 2a. A latero-lateral radiograph reveals an oblique fracture to the L6 vertebral body with severe displacement between L6 and L7 vertebrae; 2b. Immediate postoperative latero-lateral radiograph of lumbosacral surgical reduction and stabilization, using the modified dorsal segmental fixation technique; 2c. Immediate postoperative ventro-dorsal radiograph of lumbosacral surgical reduction and stabilization; 2d. The patient 6 days after surgery, raising the tail and showing normal urinary function (red arrow).



Discussion

In the first case, the fracture to the vertebral body was epiphyseal. The wounds observed along the bony protuberances, the bony callus visible on the radiograph of the femur, as well our inability to reduce the fracture during surgery indicate that the injury occurred some days before the patient was examined. This kind of rapid evolution in bone healing is typical in young animals. and it is preferable to only partially reduce the fracture and avoid additional injury to the spinal cord, which is possible when attempting complete reduction (JEFFERY, 2010). Once the spinal cord was decompressed by hemilaminectomy, it was confirmed that the spinal cord was intact, and the bone fragments were removed from the interior of the spinal canal, which likely favored patient recovery even though the vertebral fracture could not be reduced (SHARP; WHEELER, 2005).

The thoracolumbar spine is the most common region of the vertebral column to be injured in dogs, and is also at most risk for devastating neurological consequences because of the relatively small diameter of the vertebral canal compared to other areas (SHARP; WHEELER, 2005). This dog suffered from Schiff-Sherrington syndrome, which is characterized by an extension to the thoracic limbs in lateral recumbency and paraplegia. This posture is caused by damage to the *border-cells* and ascending nerve fibers in the thoracolumbar spinal cord, which, when intact, inhibit thoracic limb extension and can be compromised in some thoracolumbar spinal injuries (SHARP; WHEELER, 2005). Although this posture occurs in serious thoracolumbar spinal cord injuries, its presence does not always mean a poor prognosis (SHARP; WHEELER, 2005), as observed in the present case. There are reports describing recovery of locomotion in patients with very few nerve fibers surviving spinal injury; only 10% of axons must remain intact to maintain locomotion in dogs (WEBB et al., 2010). In streets dogs with spinal injuries, most caregivers would choose euthanasia

(MENDES; ARIAS, 2012). However, our patient had preservation of deep pain perception. The presence of deep pain sensation in spinal thoracolumbar injuries is the most important factor when evaluating patients diagnosed with exogenous vertebral trauma, because its presence indicates a high chance of recovery (SHARP; WHEELER, 2005; MENDES; ARIAS, 2012). Physiotherapy in this case was important to promote limb use and reduce muscle atrophy (JEFFERY, 2010).

According to some authors, radiography can help determine the prognosis of animals with a history of vertebral trauma when there is between 80 and 100% spinal luxation on radiographic assessment (SHARP; WHEELER, 2005; SEIM, 2005). In contrast, according to other authors, the severity of vertebral luxation has no prognostic value because prognosis can only be considered poor when deep pain perception is also absent (BRAUND, 2003; DEWEY, 2013a; WEH; KRAUS, 2013). Araújo et al. (2012) described two dogs diagnosed with a caudal thoracic vertebral fracture and luxation that go on to a functional recovery, with one dog undergoing surgery and other not receiving surgical intervention. The determining factor for good prognosis, as in our case studies, was the presence of deep pain perception. Because of fibrosis it was impossible to reduce the thoracolumbar luxation, however, according to Jeffery (2010), replacement of the bones into exactly the correct position is very much secondary to the aim of preventing further injury to the spinal cord or risking iatrogenic further injury, because the spinal cord is able to tolerate considerable deformation in shape. Therefore, incomplete reduction without further trauma is greatly preferable to complete reduction that can cause additional neural injury (JEFFERY, 2010).

In the second case, an L6 vertebral fracture was found, along with significant ventral displacement of the distal segment of the L6 and L7 vertebrae (relative to the L6 cranial segment) and more than 100% of vertebral luxation. Fractures of the L7 vertebral body are relatively more common than in

L6 vertebra, but similar fractures and luxations also occur in other vertebrae of the caudal lumbar region (JEFFERY, 2010; DEWEY, 2013b). This kind of injury is caused by forces acting directly upon the region, which typically causes oblique L6 and L7 or L7-S1 fractures (JEFFERY, 2010).

According to Sharp and Wheeler (2005), most fractures in this region can heal without surgical intervention, and even with severe luxation, the neurological disturbances are usually mild; however, this was not found in the present case, because the dog showed hindlimb paraparesis, tail paralysis and lumbar pain. Patients with 100% lumbosacral vertebral canal compromise may retain neurologic function of the pelvic limbs, anus, urinary bladder, perineum, and tail; their prognosis is favorable, and in general, the preservation of pain sensation in the areas of innervation of the cauda equina nerve roots is a favorable prognostic indicator (DEWEY, 2013b). In the present case, ventral luxation of the caudal segment was more pronounced than usually observed in other patients, and the neurological examination revealed more serious neurological deficits. Surgical treatment was advised due to the severity of the neurological damage, presence of pain, and large displacement between bone fragments (SHARP; WHEELER, 2005; DEWEY, 2013b).

The spinal canal in the lumbosacral region is spacious and occupied only by nerve roots, which can resist traumatic injury and stretching even when 100% of the spinal canal is compromised. It is estimated that approximately 80% of the damage to this region recovers (SHARP; WHEELER 2005), since the nerve roots of the cauda equina heal in a similar way to peripheral nerves (DEWEY, 2013b). According to Jeffery (2010), the recovery from peripheral nerve damage is superior to that from spinal cord injuries. In injuries to the caudal lumbosacral region, the loss of deep pain perception is not the determining factor of prognosis because there is no spinal cord in this region; instead, the limiting factor in the recovery of these animals is

urine and fecal continence (JEFFERY, 2010).

The cauda equina is a collection of nerve roots caudally located at the end of the spinal cord, which in dogs terminates close to vertebra L6. The cauda equina is composed of sciatic (L6-S2), pudendal (S1-S3), pelvic (S1-S2), and caudal (Cd1-Cd5+) nerve roots. The presence of the perineal reflex in the second case indicated integrity of the sacral segments, which is associated with the urinary continence observed in the postoperative period. Many animals with injuries to this region become ambulatory due to the integrity of the spinal segments that give rise to the femoral nerve, despite having urinary and fecal incontinence as significant complications. Despite the magnitude of injury observed in the radiographic examination, the animal successfully regained ambulation and urinary and fecal continence and the prognosis was determined based upon the presence of sensitivity and anal sphincter tone during the initial neurological examination (JEFFERY, 2010).

Conclusion

Complete luxation of the spinal canal observed radiographically does not mean a poor prognosis, and motor, sensory, and visceral functions all have the potential for recovery, as observed in these case studies. In the first case the determining factor for good prognosis was the presence of deep pain perception, and in the second case the prognosis was determined by the presence of sensitivity and anal sphincter tone during the initial neurological examination.

References

- ARAÚJO, B. M.; SILVA, A. C.; FIGUEIREDO, M. L.; FERNANDES, T. H. T.; SANTOS, C. R. O.; AMORIM, M. M. A.; TUDURY, E. A. Recuperação funcional de dois cães com fratura e luxação vertebral torácica caudal com 100% de deslocamento do canal vertebral. *Revista Científica de Medicina Veterinária - Pequenos Animais*, Curitiba, v. 10, n. 34, p. 372-377, 2012.

- BRAUND, K. G. Traumatic disorders. In: VITE, C. E. *Clinical neurology in small animals: localization, diagnosis and treatment*. New York: International Veterinary Information Service, 2003. Available at: <http://www.ivis.org/advances/Vite/braund28/chapter_frm.asp?LA=1>. Accessed at: 20 abr. 2013.
- DEWEY, C. W. Surgery of the thoracolumbar spine. In: FOSSUM, T. W. *Small animal surgery*. 4. ed. Missouri: Elsevier Mosby, 2013a. p. 1508-1528.
- _____. Surgery of the cauda equina. In: FOSSUM, T. W. *Small animal surgery*. 4. ed. Missouri: Elsevier Mosby, 2013b. p. 1529-1544.
- JEFFERY, N. D. Vertebral fracture and luxation in small animals. *Veterinary Clinics of North America: Small animal Practice*, Philadelphia, v. 40, n. 5, p. 809-828, 2010.
- KINNS, J.; MAI, W.; SEILER, G.; ZWINGENBERGER, A.; JHONSON, V.; CÁRCERES, A.; VALDES-MARTINEZ, A.; SCHWARZ, T. Radiographic sensitivity and negative predictive value for acute canine spinal trauma. *Veterinary Radiology & Ultrasound*, Massachusetts, v. 47, n. 6, p. 563-570, 2006
- KUBE, S. A.; OLBY, N. J. Managing acute spinal cord injuries. *Compendium on Continuing Education for the Practising Veterinarian*, v. 30, n. 9, p. 496-504, 2008.
- MENDES, D. S.; ARIAS, M. V. B. Traumatismo da medula espinhal em cães e gatos: estudo prospectivo de 57 casos. *Pesquisa Veterinária Brasileira*, Seropédica, v. 32, n. 12, p. 1304-1312, 2012.
- PEDRO NETO, O.; TUDURY, E. A.; SOUZA, A. F. A.; SEVERO, M. S. Substituição dos fios metálicos por fios de náilon na técnica de fixação lombar segmentar dorsal modificada. *Revista Brasileira de Ciências Veterinárias*, Rio de Janeiro, v. 9, n. 1, p. 72-74, 2002. Suplemento.
- SEIM, H. B. Cirurgia da espinha toracolombar. In: FOSSUM, T. W. *Cirurgia de pequenos animais*. 2. ed. São Paulo: Roca, 2005. p. 1259-1291.
- SHARP, N. J. H.; WHELEER, S. J. Trauma. In: _____. *Small animal spinal disorders*. 2. ed. Philadelphia: Mosby, 2005. p. 281-318.
- WEBB, A. A.; NGAN, S.; FOWLER, D. Spinal cord injury II: prognostic indicators, standards of care, and clinical trials. *Canadian Veterinary Journal*, Alberta, v. 51, n. 6, p. 598-604, 2010.
- WEH, M.; KRAUS, K. H. Spinal fractures and luxations. In: TOBIAS, K. M.; JOHNSTON, S. *Veterinary surgery. Small animal*. St Louis: Elsevier Saunders, 2013. p. 487-503.