

# Cutaneous myxosarcoma in a Syrian hamster (*Mesocricetus auratus*)

## Mixossarcoma cutâneo em um Hamster Sírio

Didier Quevedo Cagnini<sup>1\*</sup>; Marta Cristina Thomas Heckler<sup>1</sup>; Carla Fredrichsen Moya-Araujo<sup>2</sup>; Gustavo Henrique Marques Araújo<sup>1</sup>; Renée Laufer Amorim<sup>3</sup>

### Abstract

The pathological findings in a 2-years-old Syrian hamster (*Mesocricetus auratus*) with a cutaneous myxosarcoma are described. Grossly, there was a large cutaneous mass in the right cervical region. Microscopical evaluation revealed a myxosarcoma characterized by pleomorphic, fusiform cells loosely arranged, randomly distributed, and presenting a moderate amount of basophilic amorphous stroma. There were hemorrhagic areas within the tumor. The basophilic amorphous stroma was positive to Alcian blue confirming the presence of a mucopolysaccharide matrix. Immunohistochemically, the neoplastic cells expressed vimentin, and were negative for cytokeratin or glial fibrillary acidic protein (GFAP).

**Key words:** Hamster, neoplasia, myxosarcoma, pathology

### Resumo

São descritos os achados anatomopatológicos de um caso de mixossarcoma cutâneo em um Hamster Sírio de 2 anos de idade. Macroscopicamente, foi evidenciada um grande massa cutânea na região cervical lateral direita. A microscopia revelou a presença de um mixossarcoma caracterizado por células fusiformes pleomórficas, frouxamente arranjadas, distribuídas aleatoriamente e, apresentando quantidade moderada de substância basofílica amorfa no estroma e áreas hemorrágicas. O estroma basofílico amorfo foi positivo na coloração Alcian blue, confirmando a presença de matriz mucopolissacarídea. Na imunoistoquímica, as células neoplásicas expressaram vimentina e foram negativas para a marcação de citoqueratina e proteína ácida fibrilar (GFAP).

**Palavras-chave:** Hamster, neoplasia, mixossarcoma, patologia

### Introduction

Myxosarcomas, also called fibromyxosarcomas, are malignant neoplasms derived from fibroblasts or other primitive mesenchymal cells that produce prominent extracellular matrix composed of mucin (BERMAN et al., 1992; GOLDSCHMIDT; SHOFR, 1992; OLIVEIRA et al., 1999; GOLDSCHMIDT; HENDRICK, 2002).

These tumors are composed of spindle cells supported by a prominent, mucopolysaccharide-rich stroma. Due to the fact that myxoma/myxosarcoma and fibroma/fibrosarcoma may be histologically very similar, the differentiation between both categories relies mostly on the presence of mucinous stroma in the former (GOLDSCHMIDT; HENDRICK, 2002).

<sup>1</sup> Doutorando do Programa de pós-graduação em Medicina Veterinária, FMVZ, UNESP, Botucatu, SP. E-mail: didiercagnini@yahoo.com.br; martacth@gmail.com; ghmaraujo@uol.com.br

<sup>2</sup> Prof. Dr. da Faculdades Integradas de Ourinhos. E-mail: carlafredrichsen@yahoo.com.br

<sup>3</sup> Prof. Ass. Dr. do Depto. de Clínica Veterinária, Laboratório de Patologia Veterinária. FMVZ, UNESP. Botucatu, SP. E-mail: renee@fmvz.unesp.br

\* Autor para correspondência

Myxosarcoma has been reported in dogs (FOALE et al., 2003; RICHTER et al., 2003; GÁLAN et al., 2007; DENNIS, 2008; HEADLEY et al., 2011), cattle, rabbit (von BOMHARD et al., 2007), Syrian hamster (FABRÍZIO, 1965), tiger (SHILTON et al., 2002), birds (REECE, 1992), deer (SNYDER; DAVIES; KEISS, 1972), ferret (van ZEELAND et al., 2006), European hedgehog (SINGH et al., 2006) and humans (LIU et al., 2002). This neoplasm may occur at any site, but at least in dogs they occur most frequently in the skin. However, visceral organs such as heart, liver, spinal canal, and mesentery may also be affected (BERMAN et al., 1992; GOLDSCHMIDT; SHOFR, 1992; OLIVEIRA et al., 1999; GOLDSCHMIDT; HENDRICK, 2002; GROSS et al., 2005).

The distinction between myxoma e myxosarcoma may be difficult due to similar clinical and histological features. Histologically, both tumors are composed by stellate or spindle cells distributed in a myxomatous matrix characterized by a vacuolated, basophilic, and mucinous stroma (YAGER; SCOTT, 1993; SCOTT; MILLER; GRIFFIN, 1996; GOLDSCHMIDT; HENDRICK, 2002; GROSS et al., 2005). There is usually low cellularity, mitoses are rare, and atypia is not marked. Nuclei tend to be small and composed by aggregated chromatin. Increasing in cell density, marked pleomorphism, and high mitotic index favor a diagnosis of myxosarcoma (GOLDSCHMIDT; HENDRICK, 2002).

Myxosarcoma may be derived from a variety of tissue precursors, such as fibroblasts, chondroblasts, lipoblasts, myoblasts, or neurogenic cells (MACKENZIE, 1981). Differential diagnosis should include all neoplasms with prominent mucinous stroma, including chondrosarcoma, liposarcoma,

synovial sarcoma, smooth muscle tumors, embryonal rhabdomyosarcoma, peripheral nerve tumor, hemangiopericytoma, and mucinous adenocarcinoma (van ZEELAND et al., 2006). In addition, cutaneous mucinosis, should be included in the differential diagnosis (GOLDSCHMIDT; SHOFR, 1992).

Myxosarcoma reacts positively to vimentin by immunohistochemistry, but there are no other immunohistochemical tests that allow their differentiation from other mesenchymal neoplasms. Some peripheral nerve tumors are positive for S100 and GFAP (GROSS et al., 2005).

This paper aims to report a case of cutaneous myxosarcoma in cervical region in a Hamster.

## Case Report

A 2-year-old, 0.2 kg, female Syrian hamster (*Mesocricetus auratus*) was referred to a private veterinary clinic in Botucatu, Sao Paulo State, Brazil, with history of a fast growing cutaneous mass (4 months) at the base of the right ear. On physical examination a 4 x 4 x 6 cm, firm, non-infiltrative mass was observed in the subcutaneous tissue (Figure 1A). Due to the fast growing behavior, surgical excision was elected. During the surgical procedure it was noted that the tumor was noninfiltrative and composed of abundant and viscous stroma. The removed mass weighed 98 g and was referred to the Pathology Service at the Department of Veterinary Clinic, FMVZ-Unesp, Botucatu, for histopathological examination.

Gross examination revealed large amount of viscous, grayish fluid oozing out from the parenchyma. At the cut surface the mass was grayish-white and had cystic fluid-filled areas.



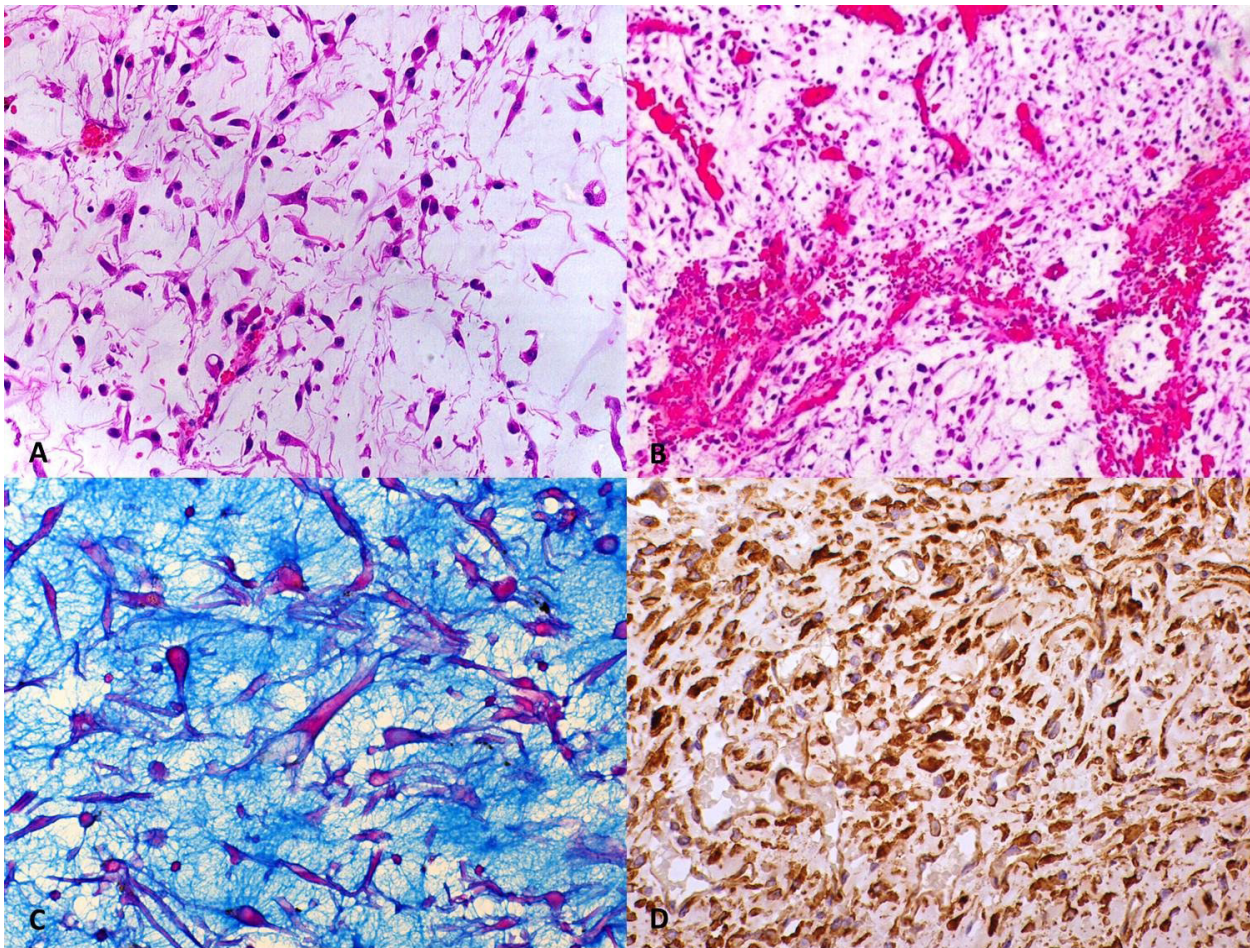
**Figure 1. Myxosarcoma in a hamster.** A. Notice the greyish tumoral growth in the right thoracic region. B. Animal recovered completely 3 months after surgery.

Histologically, the neoplasm was composed of pleomorphic, fusiform cells loosely arranged, randomly distributed, and presenting a moderate amount of basophilic amorphous stroma. Neoplastic cells varied from fusiform to stellate, with a moderate nuclear pleomorphism and scarce cytoplasm (Figure 2A). There were also hemorrhagic areas within the tumor mass (Figure 2B). Basophilic mucinous stroma was present in most sections stained with hematoxylin and eosin, being positive using Alcian blue staining (Figure 2C), as described by Shilton et al. (2002). Microscopically, von Bomhard et al. (2007) described similar findings in nine cases of myxosarcoma affecting rabbits as well Snyder, Davies and Keiss (1979), Shilton et al. (2002), Singh et al. (2006) and van Zeeland et al. (2006). Headley et al. (2011) described similar findings in a myxosarcoma in a dog, but associated with vascular invasion and metastasis to the lung, which not happen in our case.

Serial sections (4 $\mu$ m) of the neoplasm were obtained and used for immunohistochemistry. Antigen retrieval was carried out by heat treatment in 10mM citrate buffer, pH 6.0 for all primary antibodies. The primary antibodies

used consisted of monoclonal antibodies against cytokeratin AE1/AE3 (Dako, diluted 1:500), vimentin (Dako, diluted 1:2000) and GFAP (Dako, diluted 1:1000). Sections of canine CNS and skin were used as positive controls. For negative control, the primary antibody was replaced by phosphate-buffered saline. The slides were immersed with the detection system (Advance™ HRP Link, Dako) following the manufacturer's instructions. Subsequently, 3,3' diaminobenzidine tetrahydrochloride was used as chromogen in order to allow the visualization of antigen-antibody reaction. Then, the slides were counterstained using Harris's hematoxylin, dehydrated, and mounted using Permount mounting medium (Fisher Scientific, Fremont, CA) for evaluation and light microscopy.

The mesenchymal nature of the neoplastic spindle shaped cells was confirmed by their expression of vimentin (Figure 2D) and absence of expression of cytokeratin. Besides, the neoplastic cells do not react to GFAP antibody, which could exclude the peripheral nerve sheath tumour as a diagnosis in this case. Similar results were described by Headley et al. (2011) in a myxosarcoma in a dog.



**Figure 2. Myxosarcoma in a hamster.** **A.** Presence of loosely aggregated stellate and fusiform neoplastic cells. (Hematoxylin and eosin, 200x). **B.** Hemorrhagic areas within the neoplastic cells proliferation. (Hematoxylin and eosin, 100x). **C.** The neoplastic cells are in a dense mucopolysaccharide matrix (blue). (Alcian blue, 400x) **D.** Vimentin positive cytoplasmic immunorexpression in the neoplastic cells. (200x).

The animal presented full recovery from surgery (Figure 1B) and remained alive for over a year.

Myxosarcomas are soft, mucous and can adhere to all surfaces and tools used for surgical excision. The tumor borders are difficult to identify and cystic areas of degeneration can be found (GOLDSCHMIDT; SHOFER, 1992). The consistency of the tumor mass, the characteristics of the liquid, and the described cavitations were found in the case herein reported.

According to the literature, myxosarcomas are encapsulated and poorly defined neoplasms that involve the dermis and / or hypodermis with pleomorphic and fusiform cells haphazardly

distributed in a stroma rich in mucopolysaccharide and hyaluronic acid (GOLDSCHMIDT; SHOFER, 1992; GROSS et al., 2005) as described in this case. Besides, cellular morphology is variable and nuclei were generally small, with condensed chromatin.

Although the cellularity is usually low, as in myxomas, many tumors contain areas of high cellularity, resembling poorly differentiated fibrosarcomas (GOLDSCHMIDT; SHOFER, 1992; GROSS et al., 2005). As described by Goldschmidt and Shofer (1992), some areas presented increased cellularity and mitosis were infrequent. Large neoplastic masses may present hemorrhage, necrosis and fibrosis. In this case, there was multifocal,

moderate to marked hemorrhage. Secondary ulceration and inflammation may be present, but did not occur in this report. As described by Gross et al. (2005), some cysts were present.

Myxosarcoma is a rare neoplasia occurring in dogs and cats (SCOTT; MILLER; GRIFFIN, 1996) and there are few reports describing this neoplasm in other species. The association of clinical, surgical, histopathological, histochemical and immunohistochemical findings, allowed the diagnosis of myxosarcoma in the hamster herein reported.

## References

- BERMAN, L. D.; SOTO, E.; CHESTEMA, F. C. Tumors of the soft tissues In: TURUSOV, V. S. *Pathology of tumors in laboratory animals. Volume III – tumors of the hamster*. Lyon: International Agency for Research on Cancer, 1992. p. 293-325.
- DENNIS, R. Imaging features of orbital myxosarcoma in dogs. *Veterinary Radiology & Ultrasound*, v. 49, n. 3, p. 256-263, 2008.
- FABRÍZIO, A. M. An induced transmissible sarcoma in hamsters: eleven-year observation through 288 Passages. *Cancer Research*, v. 25, p. 107-117, 1965.
- FOALE, R. D. S.; WHITE, R. A.; HARLEY, R.; HERRTAGE, M. E. Left ventricular myxosarcoma in a dog. *Journal of Small Animal Practice*, v. 44, p. 503-507, 2003.
- GOLDSCHMIDT, M. H.; HENDRICK, M. J. Tumors of the skin and soft tissues. In: MEUTEN, D. J. *Tumors in domestic animals*. 4. ed. Ames: Iowa State Press. 2002. p. 45-118.
- GOLDSCHMIDT, M. H.; SHOFER, F. S. *Skin tumors of the dog and cat*. 2. ed. Oxford: Pergamon, 1992. 316 p.
- GROSS, T. L.; IHRKE, P. J.; WALDER, E. J.; AFFOLTER, V. K. Mesenchymal neoplasms and other tumors. Fibrous Tumors In: *Skin diseases of the dog and cat: clinical and histopathologic diagnosis*. 2. ed. Denmark: Blackwell Science, cap. 27, 2005. p. 710-734.
- HEADLEY, S. A.; FARIA DOS REIS, A. C.; FREDERICO, A. P.; BRACARENSE, R. L. Cutaneous Myxosarcoma with Pulmonary Metastases in a Dog. *J. Comp. Path.*, v. 145, n. 1, p. 31-34, 2011.
- LIU, S.; WANG, Z.; CHEN, A. Q.; ZHOU, G. H.; JIANG, Z. B.; DI XIAO, M. Cardiac myxoma and myxosarcoma: clinical experience and immunohistochemistry. *Asian Cardiovascular & Thoracic Annals*, v. 10, p. 8-11, 2002.
- MACKENZIE, D. H. The myxoid tumours of somatic soft tissue. *American Journal of Surgical Pathology*, v. 5, p. 443-458, 1981.
- OLIVEIRA, S. T.; CUNHA, C. G.; IWANAGA, S. H.; COELHO, H. E.; MANZAN, R.M. Mixossarcoma em mesentério de cão. *Arq. Bras. Med. Vet. Zootec.*, v. 51, n. 6, p. 537-538, 1999.
- REECE, R. L. Observations on naturally occurring neoplasms in birds in the state of Victoria, Australia. *Avian Pathology*, v. 21, n. 1, p. 3-32, 1992.
- RICHTER, M.; STANKEOVA, S.; HAUSER, B.; SCHARF, G.; SPIESS, B. M. Myxosarcoma in the eye and brain in a dog. *Veterinary Ophthalmology*, v. 6, n. 3, p. 183-189, 2003.
- SCOTT, D. W.; MILLER, W. H.; GRIFFIN, C. E. Neoplastic and Non-neoplastic Tumors. In: *Muller & Kirk's Small Animal Dermatology*. 6. ed. Philadelphia: Interlivros, cap. 20, 1996. p. 1236-1414.
- SHILTON, C. M.; THOMPSON, M. S.; MEISNER, R.; LOCK, B.; LINDSAY, W. A. Nasopharyngeal myxosarcoma in a Bengal tiger (*Panthera tigris*). *Journal of Zoo and Wildlife Medicine*, v. 33, n. 4, p. 371-377, 2002.
- SINGH, K.; BLAS-MACHADO, U.; COOPER, E. J.; CASELTINE, S. L.; NORDHAUSEN, R. Spontaneous subcutaneous myxosarcoma in a captive European hedgehog (*Erinsceus europaeus*). *Journal of Veterinary Diagnostic Investigation*, v. 18, p. 627-631, 2006.
- SNYDER, S. P.; DAVIES, R. B.; KEISS R. E. Myxosarcoma in a wapiti. *Journal of Wildlife Diseases*, v. 15, p. 307-308, 1979.
- van ZEELAND, Y. R. A.; HERNANDEZ-DIVERS, S. J.; BLASIER, M. W.; VILA-GARCIA, G.; DELONG, D.; STEDMAN, N. L. Carpal myxosarcoma and forelimb amputation in a ferret (*Mustela putorius furo*). *Veterinary Record*, v. 159, p. 782-785, 2006.
- von BOMHARD, W.; GOLDSCHMIDT, M. H.; SHOFER, F. S.; PERL, L.; ROSENTHAL, K. L.; MAULDIN, E. A. Cutaneous neoplasms in pet rabbits: a retrospective study. *Veterinary Pathology*, v. 44, p. 579-588, 2007.
- YAGER, J. A.; SCOTT, D. W. The skin and appendages. In: JUBB, K. V. F.; KENNEDY, P. C.; PALMER, N. *Pathology of domestic animals*. 4. ed. San Diego: Academic, 1993. p. 531-738.

