

The immunogenicity of *Eimeria tenella* sporozoite proteins and living oocyst vaccines in broilers

Imunogenicidade de vacina com proteínas de esporozoítos e oocistos vivos de *Eimeria tenella* em frangos

Alexey Leon Gomel Bogado¹; João Luis Garcia^{2*};
Selwyn Arlington Headley¹; Odilon Vidotto²; José da Silva Guimarães Junior²

Abstract

The purpose of the present study was to evaluate the immunity of broilers inoculated with sporulated oocysts and sporozoite proteins of *Eimeria tenella* against challenge with homologous infective oocysts. Broiler chickens of Hubbard strain, females, coccidian-free, were kept in wire cages and inoculated on the third day (day 0). Three treatments were used: T1, the negative control; T2, received 500 sporulated oocysts by gavage; T3, positive control; T4, received 50 µg of sporozoite protein with Quil A; and T5, received Quil A without sporozoite protein and PBS, the last two protocols were administered via nasal route on days 0, 7, and 21. On the 31st day, all groups, with the exception of T1, were challenged with homologous virulent strain of *E. tenella* at the dose of 8.0×10^4 oocysts. Immunogenicity was assessed by carotenoids, ELISA assay, histopathological analysis, oocysts count and lesion score. Antibody kinetics were measured weekly and showed a gradual increase in levels of immunoglobulin for treatment T2 and T4, reaching a peak on day 21. Based on the parameters evaluated, a total protecting immunological effect for the infectant oocysts vaccine (T2) and partial protection for the sporozoite protein vaccine (T4) against homologous virulent strain challenge were observed.

Key words: Broiler, *Eimeria tenella*, infectant oocysts strain, sporozoite protein, immunogenicity

Resumo

O objetivo do presente estudo foi avaliar a imunidade de frangos de corte inoculados com oocistos esporulados e proteínas de esporozoítos de *Eimeria tenella* utilizando um desafio com oocistos esporulados homólogos. Frangos de corte da linhagem Hubbard, fêmeas, livres de coccidiose, foram mantidos em gaiolas de arame e inoculados no terceiro dia (dia 0). O delineamento experimental consistiu de cinco tratamentos com três repetições: T1- controle negativo; T2- recebeu 500 oocistos esporulados por gavagem; T3- controle positivo; T4- receberam 50 µg de proteína de esporozoítos adicionados a Quil-A, e finalmente o T5- que recebeu apenas Quil A e PBS, os últimos dois protocolos foram administrados pela via nasal nos dias 0, 7 e 21. No dia 31, todos os grupos, com exceção do T1, foram desafiados com uma cepa homóloga virulenta de *E. tenella* na dose de $8,0 \times 10^4$ oocistos esporulados. A imunogenicidade foi avaliada por níveis de carotenóides, ELISA, análise histopatológica, contagem de oocistos e índice de lesões. Com base nos parâmetros avaliados, a vacina de oocistos infectante (T2) mostrou uma proteção total e a vacina de proteína de esporozoítos (T4) uma proteção parcial contra o desafio homólogo com cepa virulenta.

Palavras-chave: Frangos, *Eimeria tenella*, oocistos infectantes, proteína de esporozoíto, imunogenicidade

¹ Profs. de Medicina Veterinária, Universidade Norte do Paraná, UNOPAR, Araçongas, PR. E-mail: alexey_leon@yahoo.com.br; headleysa@gmail.com

² Profs. Drs. do Deptº de Medicina Veterinária Preventiva, Universidade Estadual de Londrina, UEL/DMVP, Campus Universitário, Londrina, PR. E-mail: jlgarcia@uel.br; vidotto@uel.br; jsjg@uel.br

* Author for correspondence

Introduction

The severity of infection caused by avian coccidiosis is directly related to the number of parasites that multiply within the host (JENKINS, 2001). Further, the clinical manifestations of coccidiosis are related to a large number of infective oocysts to which susceptible birds are exposed before their fourth week of life (MARTINS et al., 2012). Oocysts accumulated in elevated quantities within the pen of birds that are between four and seven weeks of age (WILLIAMS, 1998), can result in severe economic losses to the poultry industry, which could attain \$ 3 billion USD annually worldwide (WILLIAMS, 1999).

Consequently, preventive infection control measures, such as the addition of anticoccidial drugs to feedstuff, are necessary to curb cost. However, this method has at least three setbacks: parasite resistance to the anticoccidial drug (VERMEULEN; SCHAAP; SCHETTER, 2001); public concern with chemical residues of foodstuff (MIN; DALLOUL; LILLEHOJ, 2004); and the withdrawal of these drugs as a requirement of importing markets (SHIRLEY; SMITH; BLAKE, 2007).

Alternative to the use of anticoccidial drugs is the development of strategies aimed at inducing protective immunity against the parasite due to the reduction of oocysts eliminated by birds into the environment. Accordingly, this study evaluated and compared the immunogenicity developed by broiler chicks immunized with infective oocysts and sporozoite proteins of *Eimeria tenella* against homologous infective oocysts.

Materials and methods

Experiment location

The experiment was done at the Laboratory of Parasitology and Parasitic Disease from Department of Preventive Veterinary Medicine, Universidade Estadual de Londrina (UEL). All procedures using

animals were approved by Animal Experimentation Ethics Committee (AEEC, registered under number 52/07).

Oocysts purification and sporozoite excystation

Eimeria tenella oocysts were obtained from homogenized cecal tissue as previously described (LONG, 1971). Briefly, 80 2-week-old chickens were infected by gavages with 8×10^4 sporulated oocysts of *E. tenella*. Oocysts were isolated from the cecum seven days after inoculation, sterilized in sodium hypochlorite (2.5%), and sporulated as described (SCHMATZ; CRANE; MURRAY, 1984). After sporulation, oocysts were either kept for challenge use, or used for sporozoite excystation. The sporulated oocysts were washed thrice in 10 mM phosphate buffered saline (PBS, pH 7.5), suspended in 50 ml of cold PBS in a 50 ml-tube containing 3-mm glass beads, and then homogenized by vortex (5-min). The suspension was then pelleted at 1600g for 10 min, resuspended in 1M sucrose, and centrifuged. The sporocysts were removed from the pellet and resuspended in 50 ml-tube containing 0.25% (w/v) Trypsin, and 4% (w/v) taurodeoxycholic acid (Sigma) in PBS, and then maintained for 45 min at 42 °C in a shaking water bath. The excysted sporozoites were transformed into pellets by centrifugation for 20 min at 700g, and the supernatant carefully decanted. The sporozoites were then washed thrice in PBS, and prepared at concentrations of 10^7 sporozoites/ml.

Production of sporozoite antigen

The sporozoites, previously obtained, were sonicated and separated by centrifugation (10 000 xg during 15 min at 4°C). The supernatant collected and the protein concentration was determined as described (BRADFORD, 1976). This antigen was used for the immunization, ELISA, and evaluation of peripheral blood lymphocyte proliferation (PBL).

Experimental design

Coccidia-free, Hubbard female broiler chicks were obtained from a commercial hatchery and maintained in wire cages (group involved 12 chicks/m²). These birds were kept in coccidia-free environment, where water and food was given *ad libitum*. The experimental design consisted of five treatments with three replicates, having 12 birds per each replicate, in a completely randomized model. The ration used was in accordance with the specification of the local poultry industry (starter, grower, and finisher), without the addition of anticoccidial drugs. The protocol strategy used is outlined in Table 1. The treatments consisted of T1 (unvaccinated, unchallenged – negative control), T2 (vaccinated with infective oocysts), T3 (unvaccinated, challenged – positive control),

T4 (vaccinated with sporozoite protein), and T5 (adjuvant control group, challenged). T2 birds were infected at day 0 with 500 sporulated oocysts and kept in litter pens throughout the entire experiment. The treatment for T3, T4, and T5 birds began at day 0, with boosters at days 7 and 21 of the experiment. The treatments started when chicks were 3-day old, where was considered day zero of the experiment. Birds from all groups, except those from T1, were challenged on day 31 with 8.0×10^4 sporulated oocysts of *E. tenella*. The following disease parameters were assessed during the immunogenicity evaluation: oocyst count at the cecum; ELISA test, peripheral blood lymphocyte proliferation, quantification of carotenoids in chicken plasma, histopathological analysis, and lesion score (LS).

Table 1. Immunization strategy for vaccine evaluation.

Groups	Treatment	Immunization (days)
T1 (n=12)	unvaccinated, unchallenged (negative control)	ND
T2 (n=12)	vaccinated with 500 infective oocysts administered by gavage	0
T3 (n=12)	unvaccinated, challenged (positive control)	ND
T4 (n=12)	vaccinated with 50 µg of sporozoite protein + Quil A administered by the nasal route	0, 7, and 21
T5 (n=12)	vaccinated with Quil A without sporozoite protein + PBS administered by the nasal route	0, 7, and 21

ND=Not done.

Source: Elaboration of the authors.

Oocyst count, lesion score, and histopathological evaluation

These parameters were evaluated by examining five animals, randomly selected from each group after euthanasia on the 7th day after challenge. Gross alterations were determined as previously described (JOHNSON; REID, 1970). For T2 birds, the number of oocysts per gram of litter (OPG-L) was determined every three days until challenge. This was achieved by collecting five handpicked samples of litter containing feces from the four corners

and the center of each pen. These were placed in polythene bags (one per pen) and then thoroughly homogenized. Additionally, the number of oocysts per gram of cecal content (OPG-C) was determined for birds in all groups one week after challenge. The percentage of protection was calculated as described (ROSE; MOCKETT, 1983): % Prot. = [(number of oocysts from control chickens – number of oocysts from vaccinated chickens)/ number of oocysts from control chickens] x 100%.

The histopathological evaluation was done

as described (GARCIA et al., 2008). Briefly, intestinal sections of the birds were collected at necropsy, fixed in 10% buffered formalin solution, and routinely processed for histopathological evaluation. The intensity of the histopathological alterations observed was estimated based on the principal lesions: villous atrophy and fusion; regeneration of superficial epithelial cells; presence of parasite; necrosis and dilation of intestinal crypts; inflammatory influx; and hemorrhage. The degree of intensity was estimated as 0–3; where 0, indicates the absence of any identified lesion; 1, discrete; 2, moderate; and 3, severe lesion.

Collection of blood for the carotenoids and ELISA assay

This was achieved by collecting 1 ml of peripheral blood (with and without EDTA) from one bird of each replication of the treatments being evaluated on the 7th, 14th, 21th, 31th, and 38th, days post-immunization for the ELISA assay.

Quantification of carotenoids in chicken plasma

The carotene was extracted from 150 ml of plasma, diluted (1:10) with acetone (P.A.), homogenized, and then centrifuged (10000xg during 10 min at 4°C) as described (ALLEN et al., 1996). The supernatant was removed and then evaluated by spectrophotometer (Cintra 20, GBC Scientific Equipment Pty Ltd, Victoria, Australia) at 446nm optical density. The plasmatic carotenoid concentration ($\text{mg}\cdot\text{mL}^{-1}$) was calculated based on the extinction coefficient of lutein in acetone, $E_{1\text{cm}}^{1\%} = 2340$ (MELENDEZ-MARTINEZ et al., 2007).

Immunoenzymatic assay (ELISA)

Serum samples were used to determine antibody kinetics. The ELISA assay was done as described (GARCIA et al., 2008). The dilutions were established by using comparisons of the dilutions exiting between the serum, antigens, and conjugate.

Statistical analyses

Data were evaluated by variance analysis (ANOVA) using the General Linear Model (GLM) and, when the null hypotheses were rejected ($p < 0.05$), the averages of the variables for cecum-derived OPG, ELISA assay, and lutein levels were compared by using the Tukey multiple comparison test. The gross lesions and histopathological scores were analyzed by using the KruskalWallis test; when $p < 0.05$, the multiple-comparison Dunn test was applied. Data transformations were done by using the Boxcox procedure when there was an absence of normality and variance homogeneity. All analyses were performed by using Minitab V14 for Windows (Minitab Inc, State College, USA).

Results

Oocyst count, lesion score, histopathological and carotenoid evaluation

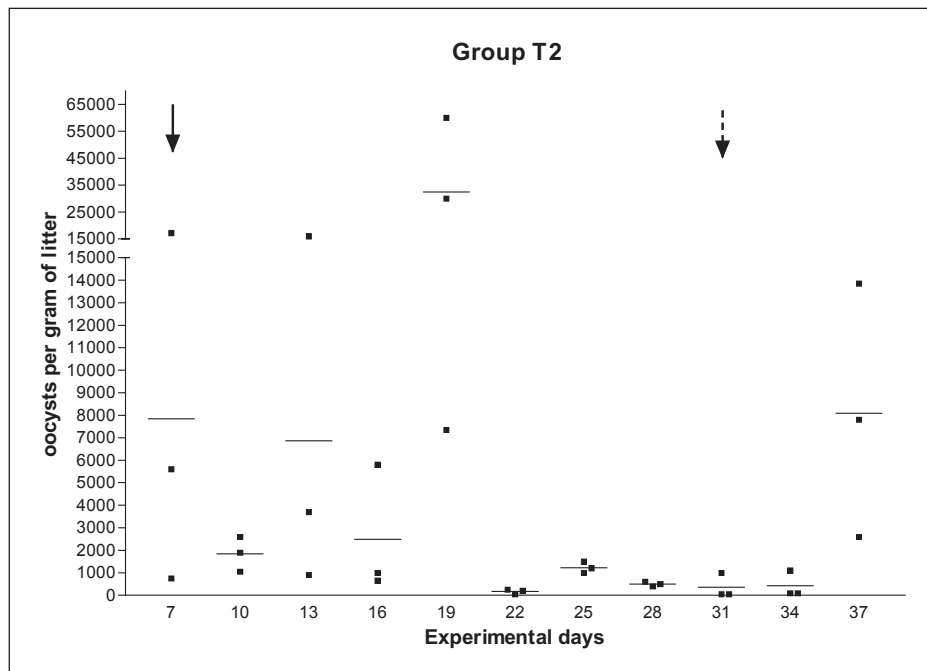
Significant statistical differences ($p < 0.001$) in the gross lesions scores were observed when the five groups were evaluated (Table 2). These differences were arranged into groups based on the intensity of the lesion: a) those with severe lesions (T3, 3.75; and T5, 3.33); b) birds with moderate lesions (T4, 1.92); and groups with discrete gross alterations (T1, 0; and T2, 0).

Significant statistical differences ($p > 0.05$) were not observed when the plasmatic lutein levels were evaluated after challenge with the homologue virulent strain (Table 2).

There was a discrete fluctuation in the liberation of oocysts (OPG-L) by T2 birds during the initial stages of the post immunization period (Figure 1). However, the concentration was remarkably increased and attained a climax at day 19 (32.450 oocysts/g of litter), and thereafter the liberation of oocysts was maintained at relatively reduced values.

Figure 1. The shedding and accumulation of oocyst by T2 birds during post immunization.

Note: complete arrow (↓) indicates day 0, beginning of the experiment, while the dashed arrow (⇩) indicates time of challenge. Animals were kill at day 37.



Source: Elaboration of the authors.

Significant statistical differences ($p < 0.01$) were observed between the groups evaluated when the number of oocysts per gram of cecal content (OPG-C) was analyzed (Table 2). Further, birds from T2 were almost totally protected (99.9%). The protection conferred to birds that were vaccinated with the sporozoite protein (T4) was 11.2% (Table 2), being significantly more elevated than those that were not vaccinated (T5), where protection was -10.9%.

Significant statistical differences ($p < 0.05$) were observed between the groups evaluated when the histological alterations were analyzed (Table 3). Significantly ($p < 0.05$) more tissue necrosis, accumulation of inflammatory influx, hemorrhage, cryptal necrosis, and the presence of parasite were observed in unvaccinated birds (T3) relative to those that were infected (T2) and vaccinated (T4). Further, birds that were infected with low number of oocysts (T2) and vaccinated (T4) demonstrated more evidence of regeneration of superficial epithelium, lymphoid tissue depletion, and epithelial

cell hyperplasia than birds from both negative (T1) and positive (T3) control groups.

Kinetics evaluation of the humoral immune response

The kinetics of the immunoglobulin response to *Eimeria* spp. are shown in Figure 2. The levels of immunoglobulin was significantly higher in birds within the T2 (optical density, OD mean = 0.377) and T4 (OD mean= 0.309) groups, where a peak in immunoglobulin response was observed in both groups at day 21 (Figure 2b and d). After this, there was a gradual decrease in immunoglobulin level (OD = 0.267). However, birds that were not vaccinated (T3) and those whose vaccine did not contain the sporozoite vaccine (T5) demonstrated concentration of immunoglobulins below the cut-off point until day 38 (Figure 2c and e). Further, the levels of immunoglobulin of T1 birds (negative control) remained below the threshold level throughout the entire post immunization of the experiment (Figure 2a).

Table 2. The effects of lesion score (LS), lutein plasma levels (LPL), oocyst count (OPG), and means and percentage protection (Prot. (%)) during immunogenicity evaluations.

Experimental groups	Immunogenicity (day 38)			
	LS	LPL $\mu\text{g}/\text{mL} \pm \text{SD}$	OPG $\times 10^5 \pm \text{SD}$	Prot. (%)
T1 ($n=12$) – unvaccinated, unchallenged (negative control)	0.00 ^b	4.65 \pm 0.59	0.045 \pm 0.048 ^b	ND
T2 ($n=12$) – vaccinated with 500 infective oocysts administered by gavage	0.17 ^b	5.64 \pm 1.16	0.017 \pm 0.006 ^b	99.9
T3 ($n=12$) – unvaccinated, challenged (positive control)	3.75 ^a	4.92 \pm 1.12	12.093 \pm 7.268 ^a	0
T4 ($n=12$) – vaccinated with 50 μg of sporozoite protein + Quil A by nasal route	1.92 ^{ab}	4.47 \pm 0.46	10.744 \pm 9.987 ^a	11.2
T5 ($n=12$) – vaccinated Quil A without sporozoite protein + PBS by nasal route	3.33 ^a	4.50 \pm 0.12	13.413 \pm 4.253 ^a	-10.9
P value	0.000	0.790	0.005	ND

Variables followed by at least one similar letter within the same column did not demonstrate significant differences ($p < 0.05$) when the Kruskal Wallis test were analyzed for the OPG and LS.

Treat. = Treatment, PV = P value, ND = Not done.

Source: Elaboration of the authors.

Table 3. Principal histopathological observations in birds challenged with sporulated oocysts.

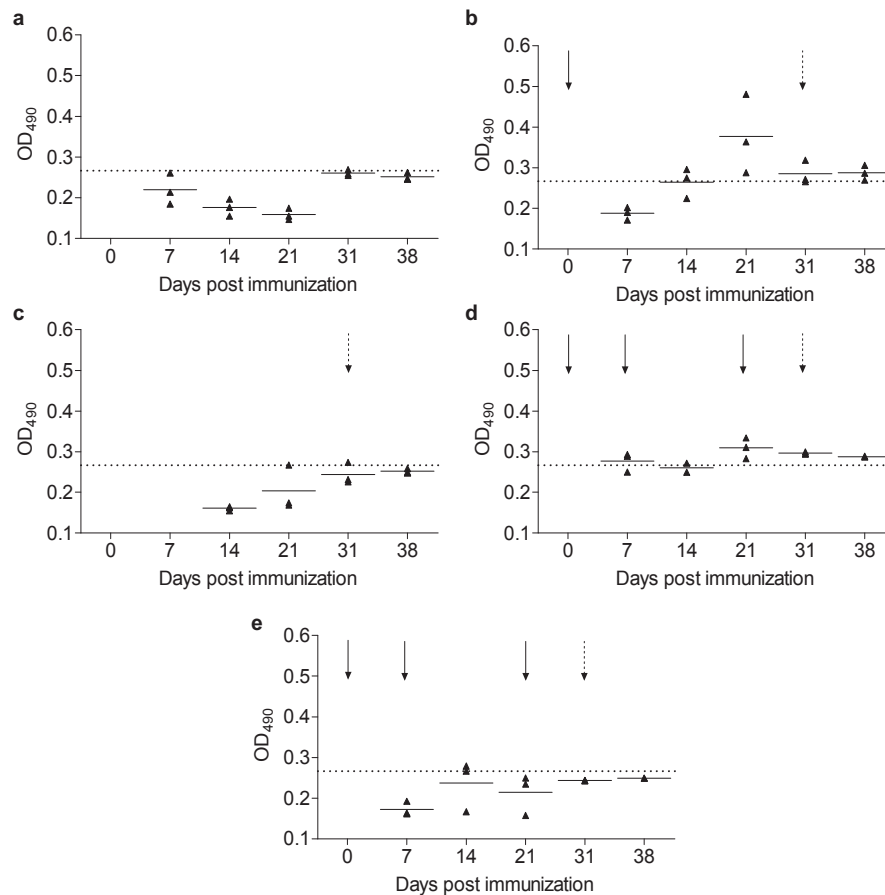
Experimental groups ($n=5$)	Principal histopathological alterations									
	Villous atrophy and fusion	Regeneration of superficial epithelium	Tissue necrosis	Inflammatory influx	Hemorrhage	Criptal dilation	Cryptial necrosis	Presence of parasite	Lymphoid depletion	Epithelial cell hyperplasia
T1 - unvaccinated, unchallenged (negative control)	1 ^b	0 ^b	2 ^{ab}	3 ^{ab}	1 ^b	0 ^b	0 ^b	0 ^b	1 ^b	2 ^{ab}
T2 - vaccinated with 500 infective oocysts administered by gavage	2 ^{ab}	3 ^a	2 ^b	2 ^b	1 ^{ab}	1 ^{ab}	1 ^b	1 ^b	2 ^a	3 ^a
T3 - unvaccinated, challenged (positive control)	3 ^a	0 ^b	3 ^a	3 ^a	2 ^a	2 ^a	3 ^a	3 ^a	0 ^b	1 ^b
T4 - vaccinated with 50 μg of sporozoite protein + Quil A by nasal route	2 ^{ab}	2 ^a	2 ^b	2 ^b	1 ^b	1 ^{ab}	2 ^{ab}	2 ^{ab}	0 ^b	3 ^a
T5 - vaccinated Quil A without sporozoite protein + PBS by nasal route	2 ^{ab}	1 ^{ab}	3 ^{ab}	3 ^{ab}	2 ^a	2 ^{ab}	2 ^{ab}	3 ^a	2 ^a	2 ^{ab}
P value	0.020	0.000	0.012	0.033	0.007	0.033	0.002	0.000	0.004	0.004

Variables followed by at least one similar letter within the same column did not demonstrate significant statistical differences ($p > 0.05$) by the Kruskal Wallis test.

Degree of intensity was estimated at 0–3; where 0, indicates the absence of a determined alteration; 1, discrete; 2, moderate; and 3, severe alterations.

Source: Elaboration of the authors.

Figure 2. The kinetics of antibody immunoglobulin response observed in birds during the post immunization period by ELISA. **a** – T1 (unvaccinated, unchallenged; negative control); **b** – T2 (received 500 infective oocysts by gavage); **c** – T3 (unvaccinated, challenged; positive control); **d** –T4 (received 50µg of sporozoite protein + Quil A by nasal route); and **e** – T5 (Quil A without sporozoite protein + PBS by nasal route). Treatments were done at days 0, 7, and 21 (complete arrows). All groups, except T1, received a challenge of 8×10^4 oocysts/bird on day 31 (dashed arrows). Dashed horizontal line indicates cut-off = 0.267.



Source: Elaboration of the authors.

Discussion

In the present study significant differences in parasitological parameters were observed when the elimination of oocysts and lesion score were compared. When the elimination of oocysts was evaluated one week after challenge, the vaccine containing infective oocysts offered greater protection to the birds relative to that with sporozoite proteins, resulting, in a reduction of 99.9% and 12.2%, respectively. Garcia et al. (2008) evaluated a nasal vaccine containing sporozoites antigens of *E. tenella* associated with ISCOM adjuvant and

obtained a protection percentage of 73.2% measured by reducing the oocysts shedding number after challenge. This difference in the reduction between these studies might be due to the different adjuvants used in each study; however, further studies need to be done to corroborate this theory.

The combined results obtained (oocysts shedding, lesion score, and the presence of parasite) indicated that T2 birds had greater protection when compared to those induced by the administration of sporozoite protein (T4). Although a low pathogenic challenge was used, the histopathological findings observed

during this study demonstrated lesions (increase of the regeneration of superficial epithelium and epithelial cell hyperplasia, as well as decrease in the levels of hemorrhage, tissue necrosis, and inflammatory influx) indicative of decreased severity of infection due to protection produced by the T2 and T4 protocols when compared with controls. Similar histopathological findings were described (GARCIA et al., 2008), but with reduced manifestation of epithelial cell hyperplasia.

The antibodies levels induced by both vaccines reached a peak on day 21 post-immunization. These results are similar to studies (HASBULLAH et al., 1992; GARG; BANERJEE; GUPTA, 1999; GARCIA et al., 2008) that reported an immunoglobulin production peak between days 10 and 37 in birds immunized with *E. tenella* oocysts or sporozoites proteins.

The plasma levels of lutein, measured one week after challenge, did not show any statistical significance ($p > 0.05$) between the treatments, due to the low pathogenicity of the challenge to which the birds were submitted.

In summary, the results of the parasitological parameters used during this study indicate that the infectant oocysts vaccine induced an immunological effect that resulted in total protection, while the sporozoite protein vaccine demonstrated partial protection against challenge by homologous virulent strain. Further, the challenge with low pathogenicity stimulated a humoral response in two treatments vaccinated. Additionally, the histopathological evaluation revealed desired changes in the vaccinated birds relative to controls, indicating that vaccination was beneficial to the chicken within this parasite-host relationship.

Acknowledgements

This research was supported by grants received from the Conselho Nacional de Desenvolvimento Científico e Tecnológico (CNPq), grants numbers

476069/2004-1, 578721/2008-2. J.L. Garcia is recipient of CNPq fellowship.

All procedures using animals were approved by Animal Experimentation Ethics Committee (AEEC, registered under number 52/07).

References

- ALLEN, P. C.; DANFORTH, H. D.; MORRIS, V. C.; LEVANDER, O. A. Association of lowered carotenoids with protection against cecal coccidiosis by diets high in n-3 fatty acids. *Poultry Science*, Champaign, v. 75, n. 8, p. 966-972, 1996.
- BRADFORD, M. M. A rapid and sensitive method for the quantitation of microgram quantities of protein utilizing the principle of protein-dye binding. *Analytical Biochemistry*, New York, v. 72, n. 1, p. 248-254, 1976.
- GARCIA, J. L.; GUIMARÃES JUNIOR, J. S.; HEADLEY, S. A.; BOGADO, A. L. G.; BUGNI, F. M.; RAMALHO, D. C.; SOUZA, L. M. *Eimeria tenella*: utilization of a nasal vaccine with sporozoite antigens incorporated into iscom as protection for broiler breeders against a homologous challenge. *Experimental Parasitology*, San Diego, v. 120, n. 2, p. 185-190, 2008.
- GARG, R.; BANERJEE, D. P.; GUPTA, S. K. Immune responses in chickens against *Eimeria tenella* sporozoite antigen. *Veterinary Parasitology*, Amsterdam, v. 81, n. 1, p. 1-10, 1999.
- HASBULLAH, T. N.; KAWAGUCHI, H.; NAKAI, Y.; OGIMOTO, K. Detection of serum antibodies in *Eimeria tenella*-infected chickens by enzyme linked immunosorbent assay (ELISA) with merozoite and oocyst antigens. *Journal of Veterinary Medical Science*, Tokyo, v. 54, n. 2, p. 201-206, 1992.
- JENKINS, M. C. Advances and prospects for subunit vaccines against protozoa of veterinary importance. *Veterinary Parasitology*, Amsterdam, v. 101, n. 3-4, p. 291-310, 2001.
- JOHNSON, J.; REID, W. M. Anticoccidial drugs: lesion scoring techniques in battery and floor-pen experiments with chickens. *Experimental Parasitology*, San Diego, v. 28, n. 1, p. 30-36, 1970.
- LONG, P. L. Maintenance of intestinal protozoa in vivo with particular reference to *Eimeria* and *Histomonas*. In: TAYLOR, A. E. R.; MULLER, R. *Isolation and maintenance of parasites in vivo*. Oxford: Blackwell Scientific Publication, 1971. p. 65-75.

- MARTINS, G. F.; BOGADO, A. L. G.; GUIMARÃES-JUNIOR, J. S.; GARCIA, J. L. Uso de vacinas no controle da coccidiose aviária. *Semina: Ciências Agrárias*, Londrina, v. 33, n. 3, p. 1165-1176, 2012.
- MELENDEZ-MARTINEZ, A. J.; BRITTON, G.; VICARIO, I. M.; HEREDI, A. F. J. Relationship between the colour and the chemical structure of carotenoid pigments. *Food Chemistry*, London, v. 101, n. 3, p. 1145-1150, 2007.
- MIN, W.; DALLOUL, R. A.; LILLEHOJ, H. S. Application of biotechnological tools for coccidia vaccine development. *Journal of Veterinary Science*, Suwon, v. 5, n. 4, p. 279-288, 2004.
- ROSE, M. E.; MOCKETT, A. P. Antibodies to coccidia: detection by the enzyme-linked immunosorbent assay (ELISA). *Parasite Immunology*, v. 5, n. 5, p. 479-489, 1983.
- SCHMATZ, D. M.; CRANE, M. S. J.; MURRAY, P. K. Purification of *Eimeria* sporozoites by DE-52 anion exchange chromatography. *Journal of Protozoology*, Lawrence, v. 31, n. 1, p. 181-183, 1984.
- SHIRLEY, M. W.; SMITH, A. L.; BLAKE, D. P. Challenges in the successful control of the avian coccidia. *Vaccine*, Kidlington, v. 25, n. 30, p. 5540-5547, 2007.
- VERMEULEN, A. N.; SCHAAP, D. C.; SCHETTER, T. P. M. Control of coccidiosis in chickens by vaccination. *Veterinary Parasitology*, Amsterdam, v. 100, n. 1-2, p. 13-20, 2001.
- WILLIAMS, R. B. A compartmentalized model for the estimation of the cost of coccidiosis to the world's chicken production industry. *International Journal for Parasitology*, Oxford, v. 29, n. 8, p. 1209-1229, 1999.
- _____. Epidemiological aspects of the use of live anticoccidial vaccines for chickens. *International Journal for Parasitology*, Oxford, v. 28, n. 7, p. 1089-1098, 1998.

